

Review paper

# Accuracy of artificial intelligence in the detection and segmentation of oral and maxillofacial structures using cone-beam computed tomography images: a systematic review and meta-analysis

Farida Abesi<sup>1,A,B,E,F</sup>, Atena Sadat Jamali<sup>2,B,E,F</sup>, Mohammad Zamani<sup>2,B,C,D</sup>

<sup>1</sup>Department of Oral and Maxillofacial Radiology, Dental Faculty, Babol University of Medical Sciences, Babol, Iran

<sup>2</sup>Student Research Committee, Babol University of Medical Sciences, Babol, Iran

## Abstract

**Purpose:** The aim of the present systematic review and meta-analysis was to resolve the conflicts on the diagnostic accuracy of artificial intelligence systems in detecting and segmenting oral and maxillofacial structures using cone-beam computed tomography (CBCT) images.

**Material and methods:** We performed a literature search of the Embase, PubMed, and Scopus databases for reports published from their inception to 31 October 2022. We included studies that explored the accuracy of artificial intelligence in the automatic detection or segmentation of oral and maxillofacial anatomical landmarks or lesions using CBCT images. The extracted data were pooled, and the estimates were presented with 95% confidence intervals (CIs).

**Results:** In total, 19 eligible studies were identified. As per the analysis, the overall pooled diagnostic accuracy of artificial intelligence was 0.93 (95% CI: 0.91-0.94). This rate was 0.93 (95% CI: 0.89-0.96) for anatomical landmarks based on 7 studies and 0.92 (95% CI: 0.90-0.94) for lesions according to 12 reports. Moreover, the pooled accuracy of detection and segmentation tasks for artificial intelligence was 0.93 (95% CI: 0.91-0.94) and 0.92 (95% CI: 0.85-0.95) based on 14 and 5 surveys, respectively.

**Conclusions:** Excellent accuracy was observed for the detection and segmentation objectives of artificial intelligence using oral and maxillofacial CBCT images. These systems have the potential to streamline oral and dental healthcare services.

**Key words:** artificial intelligence, cone-beam computed tomography, diagnosis, dentistry.

## Introduction

Cone-beam computed tomography (CBCT) is an X-ray-based imaging method with a shorter scanning time and lower radiation dose than traditional CT [1,2]. This system is commonly used in dental practice to provide three-dimensional high-resolution visualization of the structure of oral and maxillofacial lesions, helping the diagnostic and therapeutic approaches in the patients efficiently [3,4]. However, different factors can negatively influence the in-

terpretation accuracy of the prepared scans, such as low inter- and intra-observer agreement (principally for junior and less experienced practitioners) [5,6]; therefore, CBCT imaging has weaknesses as well as the advantages mentioned above.

Artificial intelligence is a wide-ranging branch of computer science (software-based) that enables machines to learn and simulate human behaviour automatically. This system has been suggested in recent years as a supplementary tool to potentially increase the diagnostic per-

## Correspondence address:

Farida Abesi, Department of Oral and Maxillofacial Radiology, Dental Faculty, Babol University of Medical Sciences, Babol, Iran, e-mail: [abesifarida1@gmail.com](mailto:abesifarida1@gmail.com)

## Authors' contribution:

A Study design · B Data collection · C Statistical analysis · D Data interpretation · E Manuscript preparation · F Literature search · G Funds collection

formance of other imaging instruments in dental practice, such as CBCT [7,8].

Several studies have assessed the diagnostic performance of artificial intelligence integrated with CBCT imaging in relation to oral and maxillofacial anatomical landmarks and lesions. In this regard, the researchers have reported differing values of accuracy [9-11]. However, no comprehensive studies have endeavoured to resolve these conflicting data. Therefore, in the present study, we aimed to conduct a contemporaneous systematic review and meta-analysis of studies reporting the accuracy of artificial intelligence in the detection and segmentation of oral and maxillofacial structures, with a focus on CBCT images, to provide an overall estimate for the diagnostic performance of artificial intelligence.

## Material and methods

### Search strategy and eligibility criteria

We reported the present study based on the Preferred Reporting Items for Systematic Reviews and Meta-Analysis (PRISMA) guideline [12]. We did a literature search of the Embase, PubMed, and Scopus databases for reports published from their inception to 31 October 2022 without language restrictions using the following keywords: *artificial intelligence* OR *deep learning* OR *machine learning* OR *automatic* OR *automated* AND *cone-beam computed tomography* OR *CBCT*. The search was limited to the Title/Abstract. We enrolled original research publications that explored the accuracy of artificial intelligence in the automatic detection or segmentation of oral and maxillofacial anatomical landmarks or lesions using CBCT images. Accuracy referred to the rate of correct findings regarding all the findings observed. We excluded reviews, case reports, editorials, and letter to the editors. We also excluded duplicate publications. Reports without extractable data on the study outcome were also excluded. Finally, studies not published in full text were ineligible for inclusion. We performed a hand search of the references of the retrieved articles to capture additional papers.

### Study selection and data extraction

We independently investigated the eligibility of the sources primarily identified in the database search by screening the titles and abstracts using a pre-designed suitability form. In the next step, we collected the full texts of the relevant reports for more detailed appraisals. Any discrepancies were resolved by consensus between the reviewers. We extracted the following data from the eligible studies finally selected for inclusion: first author's name, publication year, study location (country), objective, study design, artificial intelligence technique, validation method, sample size, and accuracy value (ranging from 0.00 to 1.00). If a study used different artificial intelligence

techniques or validation methods, we considered each as a separate report. We used Google Translate for translating full texts not in English.

### Statistical analysis

We pooled the accuracy values of artificial intelligence extracted from the studies using a random-effects model to provide overall estimates. We also performed subgroup analysis according to anatomical landmarks/lesions, detection/segmentation tasks, and artificial intelligence technique. The estimates calculated were presented with 95% confidence intervals (CIs). We used the  $I^2$  index to explore the heterogeneity between the studies, which ranges from 0.0% to 100.0%; a  $p$ -value  $< 0.10$  was considered statistically significant [13]. Forest plots were generated to illustrate the results of the meta-analysis. We appraised the publication bias using a funnel plot. We also conducted a meta-regression to assess the potential influence of the publication year on the study outcome, and a  $p$ -value  $< 0.05$  was considered statistically significant; a scatter plot was drawn in this regard. All statistical analyses were carried out by Comprehensive Meta-Analysis V2 software.

## Results

### Search results and study selection

A total of 3206 records were yielded from the initial electronic database search, of which 3175 papers were excluded because of either duplication or unsuitability. Full texts of the remaining 31 articles were then evaluated. Ultimately, 19 studies were identified as eligible for inclusion in this systematic review and meta-analysis [9-11,14-29]. The PRISMA flowchart of the search strategy and results is presented in Figure 1.

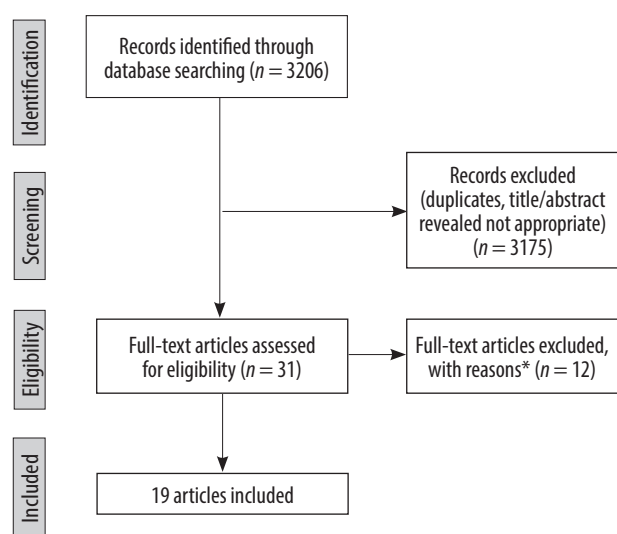

Figure 1. PRISMA flow diagram

## Study characteristics

Out of 19 individual studies included in this review, there were 4 studies from China, 4 studies from Iran, 3 studies from Belgium, 2 studies from Turkey, one study from Austria, one study from South Korea, one study from Thai-

land, one study from the USA, and 2 multicentre studies. The language of all articles was English. The publication year of the studies was between 2017 and 2022. Deep learning was the most frequently used artificial intelligence technique in the studies. Table 1 summarizes the baseline information of the included surveys.

**Table 1.** Baseline characteristics of the included studies

Study	Country	Objective	Study design	Artificial intelligence technique	Validation method	Sample size (n)
Abdolali, 2017 [14]	Iran	Classification of maxillofacial cysts	Development	Support vector machine and sparse discriminant analysis	Three-fold cross-validation	125 scans (20,000 axial images)
Abdolali, 2019 [15]	Iran, Japan	Maxillofacial lesion detection	Development	Knowledge-based support vector machine and sparse discriminant analysis	Split-sample validation	1145 scans
Chai, 2021 [16]	China	Ameloblastoma and odontogenic keratocyst diagnosis	Development	Deep learning (convolutional neural network)	Split-sample validation	350 scans
Fontenele, 2022 [9]	Belgium	Tooth segmentation	Validation	Deep learning (convolutional neural network)	Split-sample validation	175 scans (500 teeth)
Gerhardt, 2022 [10]	Belgium	Detection and labelling of teeth and small edentulous regions	Validation	Deep learning (convolutional neural network)	Split-sample validation	175 scans
Haghnegahdar, 2018 [17]	Iran	Diagnosis of temporomandibular joint disorders	Development	K-nearest neighbour	Ten-fold cross-validation	132 scans, 66 patients (132 joints) with TMD and 66 normal cases (132 joints)
Hu, 2022 [18]	China	Diagnosis of vertical root fracture	Validation	Deep learning (convolutional neural network [ResNet-50, VGG-19, DenseNet-169])	Five-fold cross-validation	552 tooth images
Johari, 2017 [11]	Iran	Detection of vertical root fractures	Development	Probabilistic neural network	Three-fold cross-validation	240 radiographs of extracted teeth (CBCT and PA), 120 intact, 120 fractured
Kirnbauer, 2022 [19]	Austria	Detection of periapical osteolytic lesions	Development and validation	Deep learning (convolutional neural network [SpatialConfiguration-Net])	Four-fold cross-validation	144 scans
Kwak, 2020 [20]	China, Finland, South Korea	Segmentation of mandibular canal	Development	Deep learning (convolutional neural network [U-net])	Split-sample validation	102 scans (49,094 images)
Lahoud, 2022 [21]	Belgium	Mandibular canal segmentation	Development and validation	Deep learning	Split-sample validation	235 scans
Lee, 2020 [22]	South Korea	Detection and diagnosis of odontogenic keratocysts, dentigerous cysts, and periapical cysts	Development	Deep learning (convolutional neural network)	Split-sample validation	2126 images (1140 panoramic and 986 CBCT images)
Lin, 2021 [23]	China	Pulp cavity and tooth segmentation	Validation	Deep learning (convolutional neural network [U-net])	External validation	30 teeth
Roongruangsilp, 2021 [24]	Thailand	Dental implant planning	Development	Deep learning (region-based convolutional neural network)	Split-sample validation	184 scans
Serindere, 2022 [25]	Turkey	Diagnose of maxillary sinusitis	Development	Deep learning (convolutional neural network)	Five-fold cross-validation	296 images
Setzer, 2020 [26]	USA	Periapical lesions detection	Development	Deep learning (convolutional neural network)	Five-fold cross-validation	20 volumes (61 roots)

Table 1.

Study	Country	Objective	Study design	Artificial intelligence technique	Validation method	Sample size (n)
Sorkhabi, 2019 [27]	Iran	Alveolar bone density classification	Development	Deep learning (convolutional neural network)	Split-sample validation	83 scans (207 surgery target areas)
Wang, 2021 [28]	China	Segmentation of oral lesion	Validation	Deep learning (convolutional neural network)	External validation	90 scans
Yilmaz, 2017 [29]	Turkey	Diagnosis of the periapical cyst and keratocystic odontogenic tumour	Development	Support vector machine	Ten-fold cross-validation, split-sample validation, leave-one-out cross validation	50 dental scans

CBCT – cone-beam computed tomography

### Overall accuracy

Nineteen individual studies reported the diagnostic accuracy of artificial intelligence using oral and maxillofacial CBCT images. The lowest and highest accuracy values reported were 0.78 and 1.00, respectively. Analysis of the studies showed that the overall pooled diagnostic accuracy of artificial intelligence was 0.93 (95% CI: 0.91-0.94;  $I^2 = 93.3\%$ ,  $p < 0.001$ ) (Figure 2). The funnel plot was suggestive of publication bias (Figure 3). Meta-regression analysis revealed that the publication year explained the heterogeneity for the outcome ( $\beta = -0.137$ ,  $p = 0.045$ ) (Figure 4).

### Accuracy by anatomical landmarks and lesions

There were 7 individual studies that reported the diagnostic accuracy of artificial intelligence for oral and maxillofacial anatomical landmarks using CBCT images. Analysis of these studies demonstrated that the pooled diagnostic accuracy of artificial intelligence was 0.93 (95% CI: 0.89-0.96;  $I^2 = 90.3\%$ ,  $p < 0.001$ ) for anatomical landmarks. In addition, the diagnostic accuracy of artificial intelligence for oral and maxillofacial lesions was investigated in 12 studies. According to the analysis of these studies, the overall pooled diagnostic accuracy of artificial intelligence was 0.92 (95% CI: 0.90-0.94;

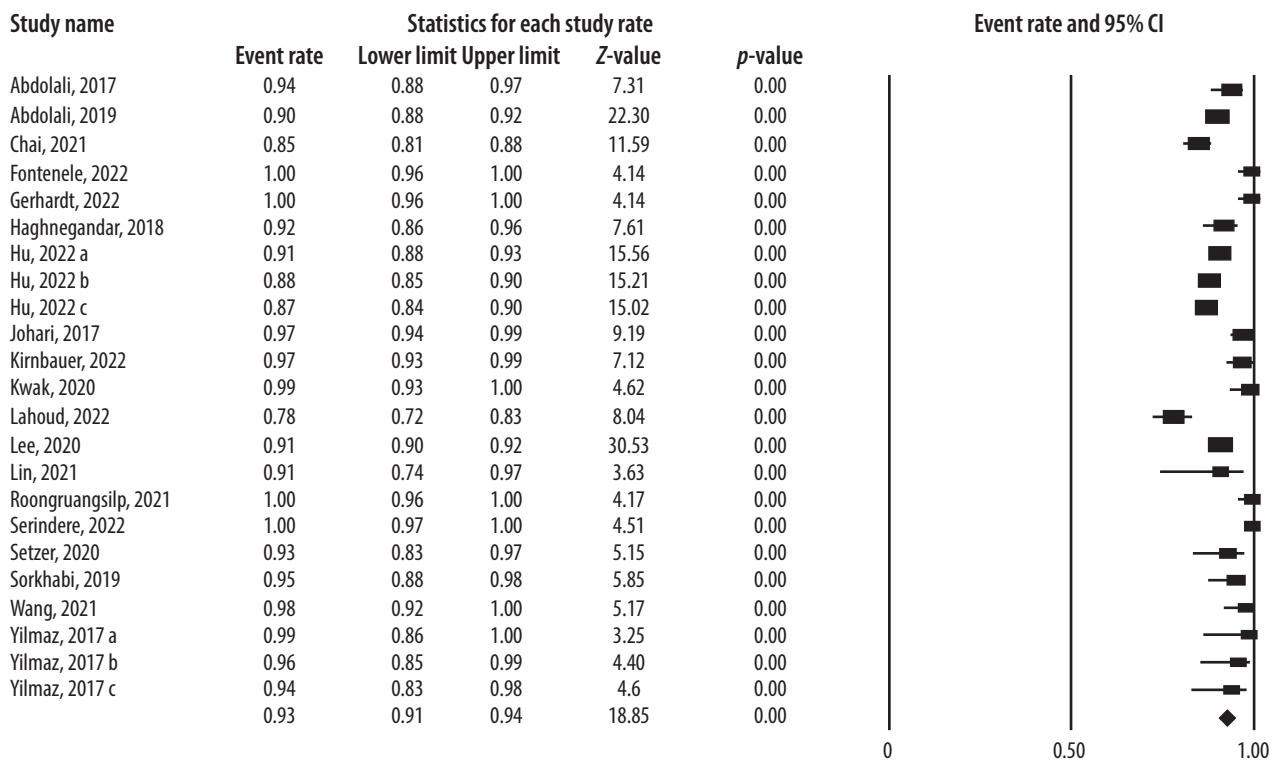
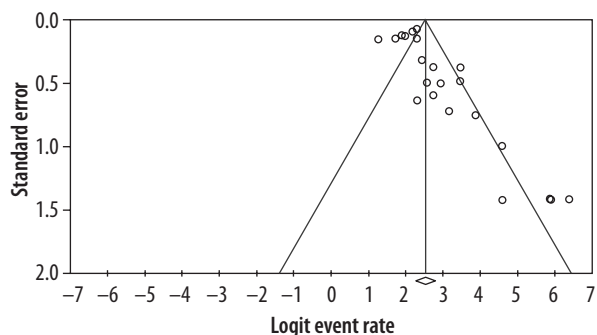
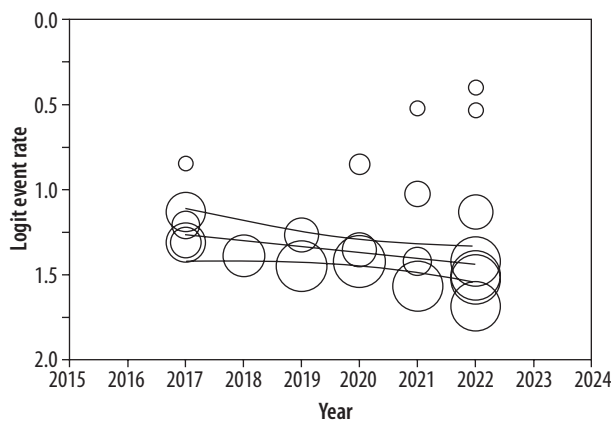


Figure 2. Diagnostic accuracy of artificial intelligence using oral and maxillofacial cone-beam computed tomography imaging



**Figure 3.** Funnel plot to assess publication bias across studies assessing diagnostic accuracy of artificial intelligence using oral and maxillofacial cone-beam computed tomography imaging



**Figure 4.** Scatter plot of the association between publication year and logit event rate for diagnostic accuracy of artificial intelligence using oral and maxillofacial cone-beam computed tomography imaging

Study name	Anatomical landmarks/ Lesions	Statistics for each study rate					Event rate and 95% CI
		Event rate	Lower limit	Upper limit	Z-value	p-value	
Fontanale, 2022	Anatomical landmarks	1.00	0.96	1.00	4.14	0.00	
Gerhardt, 2022	Anatomical landmarks	1.00	0.96	1.00	4.14	0.00	
Kwak, 2020	Anatomical landmarks	0.99	0.93	1.00	4.62	0.00	
Lahoud, 2022	Anatomical landmarks	0.78	0.72	0.83	8.04	0.00	
Lin, 2021	Anatomical landmarks	0.91	0.74	0.97	3.63	0.0	
Roongruangsip, 2021	Anatomical landmarks	1.00	0.96	1.00	4.17	0.00	
Sorkhabi, 2019	Anatomical landmarks	0.95	0.88	0.98	5.85	0.00	
		0.93	0.89	0.96	8.57	0.00	
Abdolali, 2017	Lesions	0.94	0.88	0.97	7.31	0.00	
Abdolali, 2019	Lesions	0.90	0.88	0.92	22.30	0.00	
Chai, 2021	Lesions	0.85	0.81	0.88	11.59	0.00	
Haghnegandar, 2018	Lesions	0.92	0.86	0.96	7.61	0.00	
Hu, 2022 a	Lesions	0.91	0.88	0.93	15.56	0.00	
Hu, 2022 b	Lesions	0.88	0.85	0.90	15.21	0.00	
Hu, 2022 c	Lesions	0.87	0.84	0.90	15.02	0.00	
Johan, 2017	Lesions	0.97	0.94	0.99	9.19	0.00	
Kimbauer, 2022	Lesions	0.97	0.93	0.99	7.12	0.00	
Lee, 2020	Lesions	0.91	0.90	0.92	30.53	0.00	
Seriidere, 2022	Lesions	1.00	0.97	1.00	4.51	0.00	
Setzer, 2020	Lesions	0.93	0.83	0.97	5.15	0.00	
Wang, 2021	Lesions	0.98	0.92	1.00	5.17	0.00	
Yilmaz, 2017 a	Lesions	0.99	0.86	1.00	3.25	0.00	
Yilmaz, 2017 b	Lesions	0.96	0.85	0.99	4.40	0.00	
Yilmaz, 2017 c	Lesions	0.94	0.83	0.98	4.62	0.00	
		0.92	0.90	0.94	17.06	0.00	

**Figure 5.** Diagnostic accuracy of artificial intelligence by anatomical landmarks and lesions

$I^2 = 95.1\%$ ,  $p < 0.001$ ) for lesions. Figure 5 visualizes the results of the subgroup analysis by anatomical landmarks and lesions.

**Accuracy of detection and segmentation**

Figure 6 displays the forest plot of the pooled accuracy of artificial intelligence in detecting and segmenting oral and maxillofacial structures using CBCT images. Analysis of 14 studies reporting the information on the detection accuracy indicated that the pooled accuracy of detection for artificial intelligence was 0.93 (95% CI: 0.91-0.94;  $I^2 = 94.7\%$ ,  $p < 0.001$ ). Also, based on the analysis of 5 studies that assessed the segmentation accuracy

of artificial intelligence using the CBCT system, the overall pooled accuracy of segmentation for artificial intelligence was 0.92 (95% CI: 0.85-0.95;  $I^2 = 91.9\%$ ,  $p < 0.001$ ).

**Accuracy by artificial intelligence technique**

Fifteen studies reported the artificial intelligence accuracy using the deep learning techniques [9-11,16,18-28], and 4 studies reported the accuracy using machine learning [14,15,17,29]. According to the analysis, the pooled diagnostic accuracy of artificial intelligence was 0.93 (95% CI: 0.90-0.95;  $I^2 = 92.7\%$ ,  $p < 0.001$ ) using deep learning and 0.93 (95% CI: 0.89-0.96;  $I^2 = 94.6\%$ ,  $p < 0.001$ ) using machine learning.

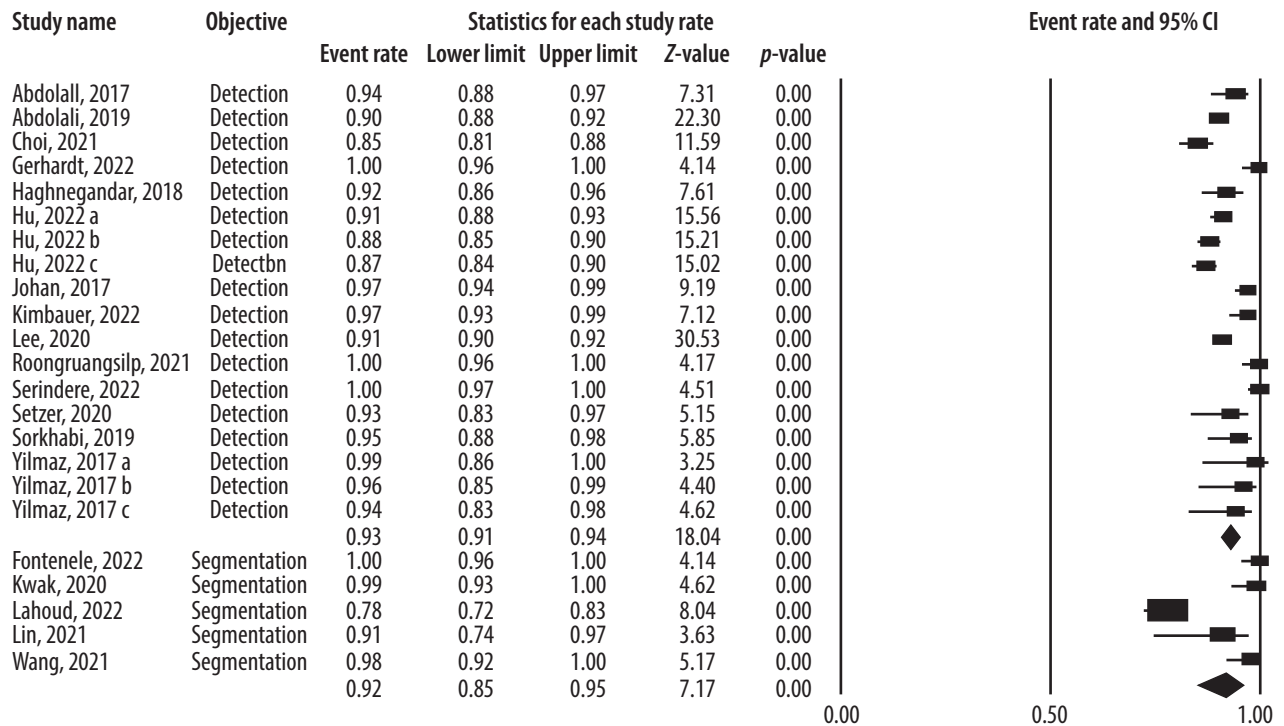


Figure 6. Diagnostic accuracy of artificial intelligence by detection and segmentation objectives

### Discussion

Artificial intelligence systems are presently utilized as auxiliary equipment for clinical and paraclinical management of dentomaxillofacial conditions due to recent technological developments in computer-aided tools [30,31]. However, the validity and reliability of these applications remained to be determined. To answer this question, several studies tried to investigate the diagnostic accuracy of artificial intelligence regarding oral and maxillofacial structures with a focus on CBCT imaging; however, the reported values varied between the surveys [8,19-23], needing a comprehensive study to gather the available data and calculate an overall estimate on this topic. In the current systematic review and meta-analysis, we assembled information from 19 studies that reported the values of artificial intelligence accuracy in the detection and segmentation of oral and maxillofacial structures using CBCT scans. We found that the overall pooled diagnostic accuracy of artificial intelligence was 0.93, which is an excellent performance. Moreover, recent publications demonstrated lower accuracy values. The accuracy value interestingly remained high when we performed subgroup analysis by anatomical landmarks and lesions; i.e. the pooled diagnostic accuracy of artificial intelligence was 0.93 for anatomical landmarks and 0.92 for lesions. Also, other subgroup analyses indicated that the pooled accuracy values of detection and segmentation were 0.93 and 0.92, respectively.

To the best of our knowledge, this is the first systematic review and meta-analysis that comprehensively assessed

the available evidence in the literature on the detection and segmentation accuracy of artificial intelligence models about oral and maxillofacial structures using CBCT images. Previous reviews either did not conduct a meta-analysis [32] or included very few studies [33]. In the present study, we systematically searched multiple databases with different keywords. Then we screened thousands of citations initially identified using strict eligibility criteria. We used a random-effects model for pooling the data to provide more conservative estimates. We also evaluated the publication bias using a funnel plot. In addition, meta-regression analysis was performed to explore the influence of publication year on the study outcome. Finally, we conducted subgroup analyses to minimize the effect of heterogeneity on the study findings.

As per the available evidence, clinicians utilize artificial intelligence systems in different oral and maxillofacial fields, typically such as orthodontics, endodontics, implantology, and oral and maxillofacial surgery [31,32]. Concerning orthodontics, researchers proposed that deep learning frameworks could be used in automatic landmark detection and cluster-based segmentation about cephalometric analysis [34,35]. With respect to endodontics, studies suggested learning models for detecting and segmenting tooth roots, alveolar bone, and periapical lesions, using methods that incorporate knowledge of orofacial anatomy, resulting in fewer images for training [7,11,26]. Regarding dental implant planning, region-based and three-dimensional deep convolutional neural network algorithms have been developed for qualitative and quantitative appraisal of alveolar bone, with accept-



able diagnostic performance [24,27,36]. Pertaining to oral and maxillofacial surgery, deep learning has been utilized for diagnosing and classifying temporomandibular joint diseases, maxillary and mandibular segmentation, and guiding oral and maxillofacial surgeons with high diagnostic performance [16,17,23]. The studies included in our review assessed different anatomical regions, such as maxillary sinuses, temporomandibular joint, dental roots, dental alveoli, periodontium, pulp cavity, and mandibular canal. Furthermore, various artificial intelligence techniques were used in the studies, but deep learning was the most common among them.

A weakness of the present review study was the high heterogeneity between the retrieved surveys, which could be explained by differences in study location, purposes, sample size, scanning device and parameters, presence of noise or artifacts, image acquisition protocols, and interobserver or intraobserver agreement. It should be mentioned that publication bias could justify the heterogeneity for the study outcome. Also, the publication year

explained the heterogeneity in the outcome according to the meta-regression results. Altogether, it is proposed that more homogeneous research be designed and carried out.

## Conclusions

The results of this systematic review and meta-analysis revealed excellent accuracy for the detection and segmentation tasks of artificial intelligence systems using oral and maxillofacial CBCT images. Artificial intelligence-based systems seem to have the potential to streamline oral and dental healthcare services and facilitate preventive and personalized dentistry. Positive and negative points and challenges of these applications need to be evaluated in further clinical studies.

## Conflict of interest

The authors report no conflict of interest.

## References

- Walter C, Schmidt JC, Rinne CA, et al. Cone beam computed tomography (CBCT) for diagnosis and treatment planning in periodontology: systematic review update. *Clin Oral Investig* 2020; 24: 2943-2958.
- Abesi F, Alimohamadi M. Cone Beam Computed Tomography (CBCT) findings of fungal sinusitis in post COVID-19 patient: a case report. *Caspian J Intern Med* 2022; 13: 307-310.
- Shukla S, Chug A, Afrashtehfar KI. Role of cone beam computed tomography in diagnosis and treatment planning in dentistry: an update. *J Int Soc Prev Community Dent* 2017; 7: S125-S136.
- Abesi F, Motaharinia S, Moudi E, et al. Prevalence and anatomical variations of maxillary sinus septa: A cone-beam computed tomography analysis. *J Clin Exp Dent* 2022; 14: e689-e693.
- Fokas G, Vaughn VM, Scarfe WC, et al. Accuracy of linear measurements on CBCT images related to presurgical implant treatment planning: a systematic review. *Clin Oral Implants Res* 2018; 29 Suppl 16: 393-415.
- Jafarzadeh M, Ansari S, Sharifshoshtari S. In vitro diagnostic accuracy of cone-beam computed tomography with variable gamma values for detection of vertical root fractures in teeth with prefabricated metal posts. *Dent Res J (Isfahan)* 2022; 19: 7. doi: 10.4103/1735-3327.336692.
- Orhan K, Bayraktar IS, Ezhov M, et al. Evaluation of artificial intelligence for detecting periapical pathosis on cone-beam computed tomography scans. *Int Endod J* 2020; 53: 680-689.
- Lahoud P, EzEldeen M, Beznik T, et al. Artificial intelligence for fast and accurate 3-dimensional tooth segmentation on cone-beam computed tomography. *J Endod* 2021; 47: 827-835.
- Fontenele RC, Gerhardt MDN, Pinto JC, et al. Influence of dental fillings and tooth type on the performance of a novel artificial intelligence-driven tool for automatic tooth segmentation on CBCT images – a validation study. *J Dent* 2022; 119: 104069. doi: 10.1016/j.jdent.2022.104069.
- Gerhardt MDN, Fontenele RC, Leite AF, et al. Automated detection and labelling of teeth and small edentulous regions on cone-beam computed tomography using convolutional neural networks. *J Dent* 2022; 122: 104139. doi: 10.1016/j.jdent.2022.104139.
- Johari M, Esmaeili F, Andalib A, et al. Detection of vertical root fractures in intact and endodontically treated premolar teeth by designing a probabilistic neural network: an ex vivo study. *Dentomaxillofac Radiol* 2017; 46: 20160107. doi: 10.1259/dmfr.20160107.
- Moher D, Liberati A, Tetzlaff J, et al. Preferred reporting items for systematic reviews and meta-analyses: the PRISMA statement. *PLoS Med* 2009; 6: e1000097. doi: 10.1371/journal.pmed.1000097.
- Higgins JP, Thompson SG, Deeks JJ, et al. Measuring inconsistency in meta-analyses. *BMJ* 2003; 327: 557-560.
- Abdolali F, Zoroofi RA, Otake Y, et al. Automated classification of maxillofacial cysts in cone beam CT images using contourlet transformation and Spherical Harmonics. *Comput Methods Programs Biomed* 2017; 139: 197-207.
- Abdolali F, Zoroofi RA, Otake Y, et al. A novel image-based retrieval system for characterization of maxillofacial lesions in cone beam CT images. *Int J Comput Assist Radiol Surg* 2019; 14: 785-796.
- Chai ZK, Mao L, Chen H, et al. Improved diagnostic accuracy of ameloblastoma and odontogenic keratocyst on cone-beam CT by artificial intelligence. *Front Oncol* 2021; 11: 793417. doi: 10.3389/fonc.2021.793417.
- Haghnegahdar AA, Kolahi S, Khojastepour L, et al. Diagnosis of temporomandibular disorders using local binary patterns. *J Biomed Phys Eng* 2018; 8: 87-96.
- Hu Z, Cao D, Hu Y, et al. Diagnosis of in vivo vertical root fracture using deep learning on cone-beam CT images. *BMC Oral Health* 2022; 22: 382. doi: 10.1186/s12903-022-02422-9.

19. Kirnbauer B, Hadzic A, Jakse N, et al. Automatic detection of periapical osteolytic lesions on cone-beam computed tomography using deep convolutional neuronal networks. *J Endod* 2022; 48: 1434-1440.
20. Kwak GH, Kwak EJ, Song JM, et al. Automatic mandibular canal detection using a deep convolutional neural network. *Sci Rep* 2020; 10: 5711. doi: 10.1038/s41598-020-62586-8.
21. Lahoud P, Diels S, Niclaes L, et al. Development and validation of a novel artificial intelligence driven tool for accurate mandibular canal segmentation on CBCT. *J Dent* 2022; 116: 103891. doi: 10.1016/j.jdent.2021.103891.
22. Lee JH, Kim DH, Jeong SN. Diagnosis of cystic lesions using panoramic and cone beam computed tomographic images based on deep learning neural network. *Oral Dis* 2020; 26: 152-158.
23. Lin X, Fu Y, Ren G, et al. Micro-computed tomography-guided artificial intelligence for pulp cavity and tooth segmentation on cone-beam computed tomography. *J Endod* 2021; 47: 1933-1941.
24. Roongruangsilp P, Khongkhunthian P. The learning curve of artificial intelligence for dental implant treatment planning: a descriptive study. *Appl Sci* 2021; 11: 10159.
25. Serindere G, Bilgili E, Yesil C, et al. Evaluation of maxillary sinusitis from panoramic radiographs and cone-beam computed tomographic images using a convolutional neural network. *Imaging Sci Dent* 2022; 52: 187-195.
26. Setzer FC, Shi KJ, Zhang Z, et al. Artificial intelligence for the computer-aided detection of periapical lesions in cone-beam computed tomographic images. *J Endod* 2020; 46: 987-993.
27. Sorkhabi MM, Khajeh MS. Classification of alveolar bone density using 3-D deep convolutional neural network in the cone-beam CT images: a 6-month clinical study. *Measurement* 2019; 148: 106945.
28. Wang X, Meng X, Yan S. Deep learning-based image segmentation of cone-beam computed tomography images for oral lesion detection. *J Healthc Eng* 2021; 2021: 4603475. doi: 10.1155/2021/4603475.
29. Yilmaz E, Kayikcioglu T, Kayipmaz S. Computer-aided diagnosis of periapical cyst and keratocystic odontogenic tumor on cone beam computed tomography. *Comput Methods Programs Biomed* 2017; 146: 91-100.
30. Gokdeniz ST, Kamburoğlu K. Artificial intelligence in dentomaxillofacial radiology. *World J Radiol* 2022; 14: 55-59.
31. Hung K, Montalvo C, Tanaka R, et al. The use and performance of artificial intelligence applications in dental and maxillofacial radiology: a systematic review. *Dentomaxillofac Radiol* 2020; 49: 20190107. doi: 10.1259/dmfr.20190107.
32. Mureşanu S, Almăşan O, Hedeşiu M, et al. Artificial intelligence models for clinical usage in dentistry with a focus on dentomaxillofacial CBCT: a systematic review. *Oral Radiol* 2023; 39: 18-40.
33. Badr FF, Jadu FM. Performance of artificial intelligence using oral and maxillofacial CBCT images: a systematic review and meta-analysis. *Niger J Clin Pract* 2022; 25: 1918-1927.
34. Chen R, Ma Y, Chen N, et al. Structure-aware long short-term memory network for 3d cephalometric landmark detection. *IEEE Trans Med Imaging* 2022; 41: 1791-1801.
35. Abesi F, Haghanifar S, Khafri S, et al. The evaluation of the anatomical variations of osteomeatal complex in cone beam computed tomography images. *J Babol Univ Med Sci* 2018; 20: 30-34.
36. Abdolali F, Zoroofi RA, Abdolali M, et al. Automatic segmentation of mandibular canal in cone beam CT images using conditional statistical shape model and fast marching. *Int J Comput Assist Radiol Surg* 2017; 12: 581-593.