

Original paper

Minimal apparent diffusion coefficient value of the solid component to differentiate borderline and malignant ovarian epithelial tumours: a preliminary report

Sahat B.R.E. Matondang¹, Avrilia Ekawati¹, Andrijono², Hartono Tjahjadi³, Joedo Prihartono⁴

¹Department of Radiology, Faculty of Medicine, Universitas Indonesia, Dr. Cipto Mangunkusumo Hospital, Jakarta, Indonesia

²Department of Obstetrics and Gynecology, Faculty of Medicine, Universitas Indonesia, Dr. Cipto Mangunkusumo Hospital, Jakarta, Indonesia

³Department of Anatomical Pathology, Faculty of Medicine, Universitas Indonesia, Dr. Cipto Mangunkusumo Hospital, Jakarta, Indonesia

⁴Department of Community Medicine, Faculty of Medicine, Universitas Indonesia, Dr. Cipto Mangunkusumo Hospital, Jakarta, Indonesia

Abstract

Purpose: Ovarian tumours are the second most common cause of death from gynaecological cancer. There are three types of ovarian cancer based on histopathological examination: benign, borderline, and malignant. However, it is difficult to distinguish the borderline and malignant tumours. Several studies used the apparent diffusion coefficient value to distinguish the ovarian tumour types, with various results. This preliminary report focused more on the use of the minimal ADC (mADC) value on the solid component, to differentiate borderline and malignant ovarian tumours.

Material and methods: In 21 cases of borderline ovarian tumours, of which 11 were regarded as malignant and 10 were regarded as borderline following histopathological examination, the mADC value was measured by two different radiologists by using free-hand technique. The intraclass correlation coefficient (ICC) was used to measure the reliability and agreement between the two radiologists. Receiver-operating characteristic (ROC) curves were then calculated to determine the optimum cut-off point.

Results: There were statistically significant ($p = 0.001$) of the mADC value between the borderline and malignant tumours. The intraclass correlation coefficient value showed excellent reliability and agreement between the examiners. The ROC curve showed the optimum cut-off point at $0.628 \times 10^{-3} \text{ mm}^2/\text{s}$ ($p = 0.001$), which yielded 100% sensitivity and 80% specificity.

Conclusions: The use of free-hand technique to measure the mADC value on the solid component can be valuable in differentiating borderline and malignant ovarian epithelial tumours. This result may assist clinicians in considering further treatment approaches.

Key words: malignant ovarian tumours, borderline ovarian tumours, ICC, mADC value, free-hand technique.

Introduction

Ovarian tumours are the second most common gynaecological cancer after cervical tumours. The prevalence increases with age, from 15-16 per 100,000 population in women aged 40-44 years to 57 per 100,000 population in women aged 70-74 years [1]. Epithelial tumours,

which account for about 90% of all ovarian tumours, are divided into three types based on histopathology: benign, borderline, and malignant. Differentiating borderline from malignant tumours is crucial in determining the appropriate surgical intervention, as well as the need for adjuvant therapy. This distinction is also important to accommodate the reproductive capability of patients [1-3].

Correspondence address:

Dr. Sahat Matondang, Faculty of Medicine, Universitas Indonesia, Dr. Cipto Mangunkusumo Hospital, Jakarta, Indonesia, e-mail: sahat92@yahoo.com

Authors' contribution:

A Study design · B Data collection · C Statistical analysis · D Data interpretation · E Manuscript preparation · F Literature search · G Funds collection

Studies commonly distinguished the benign and malignant ovarian tumours on magnetic resonance (MR) characteristics. However, results were varied [3,4]. Diffusion-weighted imaging (DWI) has been shown as a promising approach to determine whether ovarian tumours are benign or malignant. Li *et al.* [5] showed the difference using the apparent diffusion coefficient (ADC) on DWI, and it was 90.1% sensitive and 89.9% specific. Meanwhile, another study by Fuji *et al.* [6] suggested that the ADC was not significant in distinguishing benign from malignant ovarian tumours. Both studies were focused on benign-malignant differentiation [5,6].

Overall, it is still difficult to differentiate borderline from malignant tumours solely based on MR imaging [5-7]. Hence, this study focuses on the use of the minimal ADC (mADC) value to differentiate the borderline and malignant ovarian tumours.

Material and methods

Patient selection

This retrospective study was using secondary data from the Department of Anatomical Pathology. A total of 21 subjects from January 2016 until 2018, who were diagnosed with the borderline and malignant tumours based on histopathology and also underwent MRI using DWI-ADC technique, were included in this study.

Imaging technique and analysis

Abdominal and pelvic MR examination was performed using 1.5 T Avanto (Siemens Healthcare, Erlangen Ger-

many) or Optima (General Electric, Boston, Massachusetts, USA). Standard T1-weighted images (repetition time [TR], 500s; echo time [TE], 9.5 ms) and T2-weighted images (TR, 4000 ms; TE, 95-250 ms) were performed. Gadobenate dimeglumine (MultiHance, Bracco, Milan, Italy) contrast was injected (0.1 mmol/kg of contrast material) via antecubital vein using a power injector at a rate of 2-3 ml/s. DWI was performed with *b*-values of 0, 800, and 1000 s/mm².

Minimum ADC values were acquired using free-hand range of interest (ROI) on the ADC map with images from other sequences to define the solid area. ROI included only the solid component of the tumour, performed in area of at least 10 mm².

Free-hand technique on the solid component of all 21 subjects was performed in consensus by two radiologists with 4 and 15 years of experience, who were unaware of the histopathological results. Tumours with pelvic tissue or other organ invasion, peritoneal metastases, or extra pelvic or distant metastases were excluded from the analysis.

Data analysis

All statistical analysis was performed using commercial software (SPSS version 24; IBM corporation, Armonk NY, USA). The intraclass correlation coefficient (ICC) was used to determine the reliability between the examinations. Mann-Whitney *U* test (abnormal distribution shown by Shapiro-Wilk test) was used to test the difference of mADC between borderline and malignant. Cut-off points were then obtained using the receiver operating characteristic (ROC) analysis.

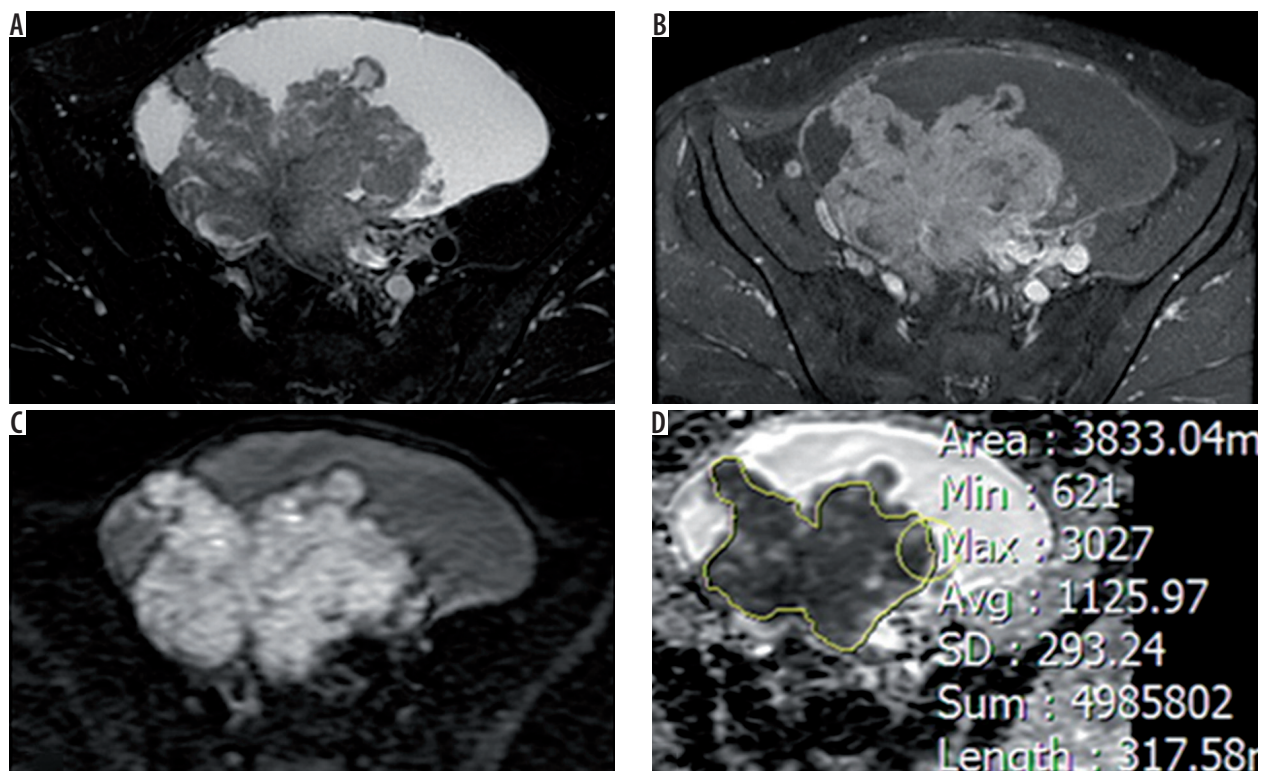


Figure 1. Free-hand range of interest of the solid component

Table 1. Intraclass correlation coefficient of ROI examination

No.	Tumour	Radiologist 1			Radiologist 2			Intraclass coefficient
		Median	Minimum	Maximum	Median	Minimum	Maximum	
1	Borderline	0.792	0.255	1.176	0.852	0.230	1.282	0.961
2	Malignant	0.292	0.082	0.611	0.440	0.120	0.711	0.947

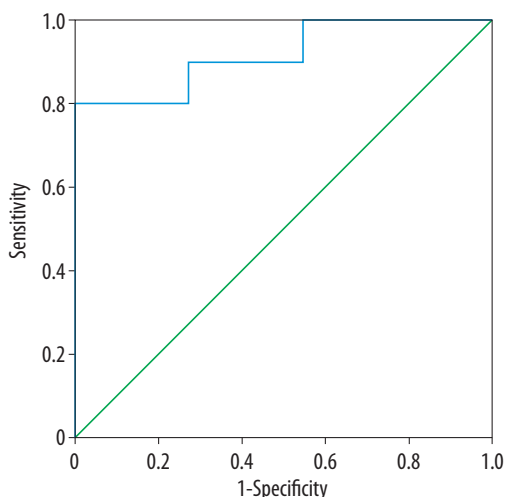


Figure 2. ROC curve of minimal apparent diffusion coefficient (mADC) value

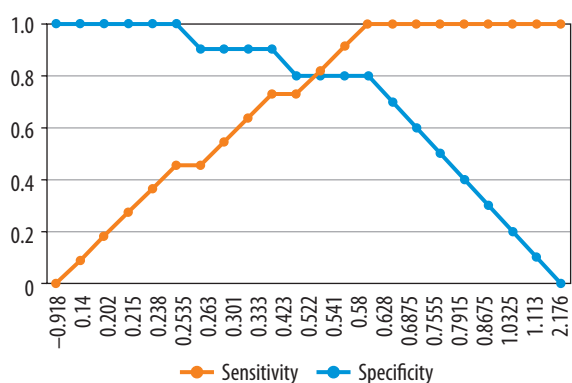


Figure 3. Sensitivity and specificity of minimal apparent diffusion coefficient (mADC) cut-off point based on ROC analysis. The value of $0.628 \times 10^{-3} \text{ mm}^2/\text{s}$ was used in this study because it represented the best optimum value of sensitivity and specificity

Table 2. Correlation between apparent diffusion coefficient (ADC) value and histopathological result

ADC value	Malignancy		Total
	Malignant	Borderline	
< 0.628	11	2	13
≥ 0.628	0	8	8
Total	11	10	21

McNemar $p = 0.500$, Kappa $R = 0.81$ ($p = 0.000$), sensitivity = 80%, specificity = 100%

Results

Figure 1 shows the solid component of ovarian tumour measurement by using free-hand ROI on the ADC map performed in an area of 10 mm^2 . The results from two dif-

ferent radiologists were then analysed with intraclass correlation coefficient (ICC), and showed they excellent reliability in both borderline and malignant tumours (0.961 and 0.947, respectively) (Table 1).

There was a significant different ($p = 0.001$) in mADC value of borderline tumours and malignant tumours. ROC curve was then performed to obtain the area under the curve (AUC) and determine the optimal cut-off point (Figure 2).

Area under curve showed mADC as an excellent (0.92 ± 0.06 , $p = 0.001$) variable to differentiate borderline from malignant tumours. Upon ROC analysis, the optimum mADC value was identified at $0.628 \times 10^{-3} \text{ mm}^2/\text{s}$ (Figure 3) with sensitivity of 100%, specificity of 80%, positive predictive value (PPV) of 84.6%, and negative predictive value (NPV) of 100% (Table 2).

Discussion

This study showed a significant difference of mADC value between the borderline and malignant ovarian tumours. In previous studies, a lower ADC value correlated with a higher tumour cellular density [7-9]. Compared to benign tumours, malignant epithelial tumours showed an increased proliferation rate, which contributes to higher cellular density [9-11]. Thus, it is suggested that the solid component of the malignant tumour demonstrates a higher restricted diffusion and appears as a low signal intensity on ADC.

The solid component of both borderline and malignant tumours was then measured by two different radiologists using a free-hand technique on the ADC map. We used the intraclass correlation coefficient (ICC) to measure the reliability and agreement between the two examiners. The ICC value in our study was 0.961 and 0.947 for the borderline and malignant tumours, respectively. This means that the reliability is excellent [12]. This measurement was also used by Li *et al.* [13].

Several studies used the ROI selection approach to differentiate borderline and malignant ovarian tumours. Mimura *et al.* [14] used the semi-automatic ROI selection to gain the ADC value and distinguish the borderline from malignant ovarian tumours. This study showed a cut-off ADC value of $0.9 \times 10^{-3} \text{ mm}^2/\text{s}$ with sensitivity of 61.9% and 93.8% [14]. The approach is different to the one used in our study because they used semi-automatic ROI, while we used a free-hand technique involving two different examiners.

The involvement of radiologists for the differentiation of the borderline and malignant ovarian tumours was also found in other studies. Denewar *et al.* [15] involved two ra-

diologists as examiners to analyse the ROI of solid components on the ADC map with the area of ROI was 10 mm². There were 60 subjects included in this study, and the cut-off point between the borderline and malignant tumours was 1.53×10^{-3} mm²/s and showed 69% sensitivity and 81% specificity [15]. Likewise, Li *et al.* [13] used a similar method to evaluate the ROI of solid components. The total sample used in this study was 52 subjects, and the cut-off point was 1.36×10^{-3} mm²/s, with 88.2% sensitivity and 88.6% specificity [13]. The most recent study was conducted by Kim [16] in 2019. This study involved 70 subjects who underwent MRI examination. Of these, 63 subjects underwent DW-MRI examinations. Two radiologists were assigned to analyse the ROI of the solid component of tumours and determine the ADC value. The cut-off point between the borderline ovarian and malignant ovarian tumours was 1.05×10^{-3} mm²/s, with 74% sensitivity and 80% specificity [16].

With the exception of Mimura *et al.*, who used a semi-automatic approach, the method of previous studies was similar to our study, i.e. two independent radiologists were assigned to evaluate the ADC value of solid components.

Our study showed the lowest result in the cut-off point of ADC value (0.628×10^{-3} mm²/s), which was statistically significant ($p = 0.001$). Moreover, this study showed the highest sensitivity and specificity among other previous studies. We suggest that a free-hand technique on the solid component of the ovarian tumours, the reliability

between the two independent radiologists, and the histopathological data play an important role in differentiating borderline and malignant ovarian tumours.

This study has several limitations. This preliminary report used small size samples, which may affect the cut-off point, sensitivity, and specificity of this study. Another limitation is that we only measured the ADC value of the solid component of the ovarian tumours, while other studies also assessed other aspects such as the vessel permeability and the cell density of the solid components [15]. Lastly, although the ICC value showed excellent reliability and agreement between the two independent radiologists, a free-hand technique still requires further validation.

Conclusion

The minimum ADC value of the solid components can be valuable. This is a highly applicable method that can assist clinicians in considering the treatment approach. As of a preliminary report, we suggest further study using a larger sample size and similar method to determine the significance of the minimal ADC value in differentiating borderline and malignant ovarian tumours.

Conflict of interest

The authors report no conflict of interest.

References

- Lalwani N, Shanbhoque AKP, Vikram R, *et al.* Current Update on Borderline Ovarian Neoplasms. *Am J Roentgenol* 2010; 194: 330-336.
- Takeuchi M, Mayumi K, Nishitani H. Diffusion-weighted magnetic resonance imaging of ovarian tumors: differentiation of benign and malignant solid components of ovarian masses. *J Comput Assist Tomogr* 2010; 34: 173-176.
- Hellyanti T, Tjahjadi H. Accuracy of frozen biopsy on ovarian tumor epithelial type. *Indonesian Pathology Journal* 2012; 21: 37-43.
- Wakefield JC, Downey K, Kyriazi S, deSouza NM. New MR techniques in gynecologic cancer. *Am J Roentgenol* 2013; 200: 249-260.
- Li W, Chu C, Cui Y, *et al.* Diffusion-weighted MRI: a useful technique to discriminate benign versus malignant ovarian surface epithelial tumors with solid and cystic components. *Abdom Radiol* 2012; 37: 897-903.
- Fujii S, Kakite S, Nishihara K, *et al.* Diagnostic accuracy of diffusion-weighted imaging in differentiating benign from malignant ovarian lesions. *J Magn Reson Imaging* 2008; 28: 1149-1156.
- Nasr E, Hamed I, Abbas I, Khalifa NM. Dynamic contrast enhanced MRI in correlation with diffusion weighted (DWI) MR for characterization of ovarian masses. *Egypt J Radiol Nucl Med* 2014; 45: 975-985.
- Mansour S, Wessam R, Raafat M. Diffusion-weighted magnetic resonance imaging in the assessment of ovarian masses with suspicious features: strengths and challenges. *Egypt J Radiol Nucl Med* 2015; 46: 1279-1289.
- Fischerova D, Zikan M, Dunder P, Cibula D. Diagnosis, treatment, and follow-up of borderline ovarian tumors. *Oncologist* 2012; 17: 1515-1533.
- McCluggage WG. The pathology of and controversial aspects of ovarian borderline tumors. *Curr Opin Oncol* 2010; 22: 462-472.
- Hauptmann S, Friedrich K, Redline R, Avril S. Ovarian borderline tumors in the 2014 WHO classification: evolving concepts and diagnostic criteria. *Virchows Arch* 2017; 470: 125-142.
- Koo TK, Li MY. A guideline of selecting and reporting intraclass correlation coefficients for reliability research. *J Chiropr Med* 2016; 15: 155-163.
- Li HM, Zhao SH, Qiang JW, *et al.* Diffusion kurtosis imaging for differentiating borderline from malignant epithelial ovarian tumors: a correlation with Ki-67 expression. *J Magn Reson Imaging* 2017; 46: 1499-1506.
- Mimura R, Kato F, Tha KK, *et al.* Comparison between borderline ovarian tumors and carcinomas using semi-automated histogram analysis of diffusion-weighted imaging: focusing on solid components. *Jpn J Radiol* 2016; 34: 229-237.
- Denewar FA, Takeuchi M, Urano M, *et al.* Multiparametric MRI for differentiation of borderline ovarian tumors from stage I malignant epithelial ovarian tumors using multivariate logistic regression analysis. *Eur J Radiol* 2017; 91: 116-123.
- Kim SH. Assessment of solid components of borderline ovarian tumor and stage I carcinoma: added value of combined diffusion- and perfusion-weighted magnetic resonance imaging. *Yeungnam Univ J Med* 2019; 36: 231-240.