

Review paper

Computed tomography scan in COVID-19: a systematic review and meta-analysis

Pouya Mahdavi Sharif^{1,2,A,B,C,D,E,F}, Mehran Nematizadeh^{1,2,A,B,C,D,E,F}, Mahdia Saghadzadeh^{1,D},
Amene Saghadzadeh^{1,3,A,C,E}, Nima Rezaei^{1,3,4,5,A,D,E}

¹Systematic Review and Meta-analysis Expert Group (SRMEG), Universal Scientific Education and Research Network (USERN), Tehran, Iran

²School of Medicine, Tehran University of Medical Sciences, Tehran, Iran

³Research Center for Immunodeficiencies, Children's Medical Center, Tehran University of Medical Sciences, Tehran, Iran

⁴Department of Immunology, School of Medicine, Tehran University of Medical Sciences, Tehran, Iran

⁵Network of Immunity in Infection, Malignancy and Autoimmunity (NIIMA), Universal Scientific Education and Research Network (USERN), Tehran, Iran

Abstract

Purpose: Computed tomography (CT) scan is a commonly used tool for the diagnosis of the novel coronavirus disease 2019 (COVID-19), similarly to reverse transcription-polymerase chain reaction (RT-PCR). Because of the limitations of RT-PCR, there is growing interest in the usability of the CT scan. The present systematic review and meta-analysis aims to summarize the available data on the CT scan features of COVID-19.

Material and methods: We conducted a systematic search in electronic databases to find eligible studies published between 1 December 2019 and 4 April 2020, which investigated the computed tomographic features of patients with COVID-19. All preprint and peer-reviewed articles were included. No language limitation was applied. For proportional data, pooled prevalence was calculated using a Freeman-Tukey double arcsine transformation, with a 95% confidence interval (CI).

Results: Eighty-six studies were eligible to be included in the meta-analysis. For 7956 patients, the most common CT findings were bilateral pattern of involvement (78%; 95% CI: 0.73-0.82; $p < 0.001$), involvement of more than 1 lobe (75%; 95% CI: 0.68-0.82; $p < 0.001$), ground-glass opacities (GGO) (73%; 95% CI: 0.67-0.78; $p < 0.001$), and peripheral distribution of signs (69%; 95% CI: 0.61-0.76; $p < 0.001$). Only 5% of patients had a normal CT scan (95% CI: 0.03-0.07; $p < 0.001$). The proportion of paediatric patients (age < 18 years) with unremarkable CT findings was higher (40%; 95% CI: 0.27-0.55; $p < 0.001$). Subgroup analysis showed that patients with the severe or critical type of COVID-19 were more likely to have pleural effusion (RR 7.77; 95% CI: 3.97-15.18; $p < 0.001$) and consolidation (RR 3.13; 95% CI: 1.57-6.23; $p < 0.001$). CT results in patients with COVID-19 were comparable with those of people having pneumonia from other causes, except for the lower incidence of consolidation (RR 0.81; 95% CI: 0.71-0.91; $p < 0.001$) and higher risk of showing GGO (RR 1.45; 95% CI: 1.13-1.86; $p < 0.001$). The mortality rate was slightly higher in patients with bilateral involvement (RR 3.19; 95% CI: 1.07-9.49; $p = 0.04$).

Conclusions: Our study results show that COVID-19 shares some features with other viral types of pneumonia, despite some differences. They commonly present as GGO along with vascular thickening, air bronchogram and consolidations. Normal CT images, lymphadenopathies, and pleural effusions are not common. Consolidations and pleural effusions correlate with more severe disease. CT features are different between COVID-19 and non-COVID-19 pneumonia. Also, they differ by age, disease severity, and outcomes within COVID-19 patients.

Key words: COVID-19, SARS-CoV-2, computed tomography, CT scan, imaging, systematic review, meta-analysis, paediatric, ground-glass opacities.

Correspondence address:

Nima Rezaei, Tehran University of Medical Sciences, Tehran, Iran, e-mail: rezaei_nima@tums.ac.ir; rezaei_nima@yahoo.com

Authors' contribution:

A Study design · B Data collection · C Statistical analysis · D Data interpretation · E Manuscript preparation · F Literature search · G Funds collection

Introduction

In December 2019, multiple pneumonia cases infected by an unknown causative agent were identified in Wuhan, China [1]. Further investigations proved that the underlying pathogen was a novel coronavirus, the seventh human-infecting one after HCoV-NL63, HCoV-229E, HCoV-OC43, HCoVHKU1, severe acute respiratory syndrome coronavirus (SARS-CoV), and Middle East respiratory syndrome coronavirus (MERS-CoV). After identifying the genetic sequence, it was named SARS-CoV-2 by the International Committee on Taxonomy of Viruses (ICTV) [2,3]. It was officially recognized as coronavirus disease 2019 (COVID-19) by the World Health Organization (WHO) on 11 February 2020. It has spread worldwide and contributed to thousands of deaths. As a result, the WHO referred to COVID-19 as a public health emergency of international concern on 30 January 2020, and later on 11 March 2020 as a pandemic [4]. As of 13 April 2020, the number of confirmed cases and deaths of COVID-19 is 1,853,155 and 114,247, respectively [5].

Before the emergence of COVID-19, 2 other β -coronaviruses, SARS-CoV and MERS-CoV, had caused epidemics beginning in 2002-2003 in China [6-8] and 2012-2013 in Saudi Arabia [9-11], respectively. Recent investigations have shown several similarities and differences between COVID-19 and the coronaviruses mentioned above in terms of clinical, epidemiological, laboratory, and radiological characteristics [12-15]. As observed in recent studies, clinical findings during the disease course may include but are not limited to fever (81-94% of cases), cough (65-78% of cases), muscle soreness or fatigue (21-65% of cases), and acute respiratory distress syndrome (ARDS) (4-29% of cases). So, a considerable portion of COVID-19 cases may progress to life-threatening conditions [16]. To prevent or manage this, early diagnosis of the disease is critical so that the isolation, monitoring, and treatment process may begin earlier, which might lead to better disease outcomes and fewer infections in the population.

Detection of the virus genome using the reverse transcription-polymerase chain reaction (RT-PCR) technique is currently the approved method for a definite diagnosis of COVID-19. However, its sensitivity is reportedly not high enough. Also, the test is time-consuming and not widely available, and false-negative results may be present because of errors in sampling methods, sampling sites, sample processing, and incorrect timing of sampling [17,18]. On the other hand, chest computed tomography (CT) is a relatively available and non-invasive method used for identifying COVID-19 cases [19]. To apply CT imaging as a valid preliminary test, it is necessary to explain the radiological features of COVID-19. Many studies have reported radiological findings of the disease in different populations, and previously published reviews inferred some general details. Considering the numerous publications that become available every day, there is a need for a more detailed description of

chest CT findings in COVID-19. Therefore, this study aims to summarize the available data regarding chest CT features in confirmed cases of COVID-19, provide more details of specific findings, clarify the findings and differences in paediatric patients, the different degrees of disease severity, and PCR-negative or non-COVID pneumonia, and evaluate the correlation between CT findings and patient outcomes.

Material and methods

The results of this meta-analysis are reported based on the preferred reporting items for systematic reviews and meta-analyses (PRISMA) statement [20].

Search strategy

We systematically searched the MEDLINE, Web of Science, and Scopus databases for relevant publications. Because of the novelty of this topic and for the reduction of publication bias, we also searched Google Scholar for the possible missing articles on other databases. Our search terms were the following: “CT”, “CT scan”, “computed tomography”, “imaging”; and “COVID19”, “SARS-CoV-2”, “Wuhan pneumonia”, “Wuhan corona”, “2019nCoV”, and “2019 novel coronavirus”. The search strategy for each database is provided with details in the supplement. No language restriction was applied. All relevant studies published between 1 December 2019 and 15 March 2020 were retrieved. We also manually searched the reference lists of reviews and relevant articles. An additional search was conducted on 4 April 2020 in MEDLINE using the same search terms.

Selection criteria

We included all peer-reviewed and non-peer-reviewed publications that had reported computed tomographic features of RT-PCR-confirmed patients with SARS-CoV-2 infection. Editorials, letters, comments, reviews, and case series with less than 10 reported cases were excluded from our search results. Two authors (P.M. and M.N.) independently conducted the title and abstract screening, and then performed a detailed review of the resulting publications. Any disagreement was consulted with another author (A.S.).

Quality assessment

We used a modified version of the Newcastle-Ottawa scale (NOS) designed for the cross-sectional studies as a tool for quality assessment [21]. This tool is concerned with three main areas of interest: sample selection, comparability of groups, and outcome. The maximum obtained score was ten stars.

Data extraction

Two authors (P.M. and M.N.) independently extracted all the relevant data about the CT features of COVID-19

patients. Because some studies had compared CT findings of confirmed COVID-19 patients with pneumonia patients of other infectious causes, the data of such patients were also retrieved with details. Extracted data consisted of the following parts: first author's name, year of publication, possible subgroups, number of cases that underwent CT scan, number of patients with normal CT findings, ground-glass opacities (GGO), consolidation, air-bronchogram, bronchial wall thickening, bronchiectasis, crazy-paving pattern, halo sign, reversed halo sign, lymphadenopathy, pleural effusion, pleural thickening, tree-in-bud sign, cavitation, vascular dilation and thickening, bilateral involvement of lungs, peripheral distribution of inflammation, the involvement of more than one lobe, and the number of each of the involved lobes (RUL, RML, RLL, LUL, and LLL). Detailed definitions for each of these signs are provided in Table 1.

Statistical analysis

All proportional and between-group meta-analyses in this study were performed using Stata release 16.0 (StataCorp, College Station, TX, USA). For proportional data, we first transformed the proportions with the Freeman-Tukey double arcsine method so that the normal distribution could be achieved and the problem with proportions being too high or too low and their confidence intervals would be resolved [22]. Reported effect estimates and confidence intervals (CI) were then back-transformed to proportions. Heterogeneity between studies was assessed using the *p*-value of Cochran's Q test and its more quantified form, *I*² statistics. We assessed publication bias using Egger's test [23].

An *I*² value of less than 40% was considered as an indicator of low heterogeneity between publications. Based on the results of the *I*² statistics, we carried out a fixed or random effects model for meta-analysis. For proportional data, the effect size (ES) was the pooled proportion of CT features, reported with a 95% CI. For the between-group analysis, risk ratio and 95% CI were calculated. A *p*-value of less than 0.05 was considered significant. Because it seems that the course of the disease is generally milder in children [24], we decided to analyse paediatric cases (age < 18 years) separately (*n* = 147; six publications [25-30]). Also, three types of subgroup analyses were considered, to assess whether the prevalence of CT findings is different between: (1) those with mild-moderate and severe-critical disease; (2) surviving and deceased patients; and (3) those with RT-PCR-confirmed COVID-19 and those with pneumonia caused by other agents. For the severity of the disease, most studies classified their cases based on either the Guidelines for the Diagnosis and Treatment of New Coronavirus Pneumonia [31] or the American Thoracic Society guidelines for community-acquired pneumonia [32].

Results

Study selection and characteristics

Our first search resulted in 547 results. After the removal of duplications, 428 publications underwent title and abstract screening. After the exclusion of irrelevant articles based on title and abstract screening, 109 articles were assessed for eligibility by full-text screening. Among these, we found 65 studies eligible to be considered for quanti-

Table 1. Definition of computed tomography findings reported in this study (from the Fleischner Society: Glossary of Terms for Thoracic Imaging) [86]

Radiologic sign	Definition
Air-bronchogram	An air bronchogram is a pattern of air-filled (low-attenuation) bronchi on a background of opaque (high-attenuation) airless lung.
Bronchiectasis	Morphologic criteria on thin-section CT scans include bronchial dilatation with respect to the accompanying pulmonary artery (signet ring sign), lack of tapering of bronchi, and identification of bronchi within 1 cm of the pleural surface.
Cavitation	A cavity is a gas-filled space, seen as a lucency or low-attenuation area, within pulmonary consolidation, a mass, or a nodule.
Consolidation	Consolidation appears as a homogeneous increase in pulmonary parenchymal attenuation that obscures the margins of vessels and airway walls.
Crazy-paving pattern	This pattern appears as thickened interlobular septa and intralobular lines superimposed on a background of ground-glass opacity, resembling irregularly shaped paving stones.
Ground-glass opacity (GGO)	On CT scans, GGO appears as hazy increased opacity of lung, with preservation of bronchial and vascular margins.
Halo sign	The halo sign is a CT finding of ground-glass opacity surrounding a nodule or mass.
Lymphadenopathy	There is a wide range in the size of normal lymph nodes. Mediastinal and hilar lymph nodes range in size from sub-CT resolution to 12 mm. Somewhat arbitrary thresholds for the upper limit of normal of 1 cm in short-axis diameter for mediastinal nodes and 3 mm for most hilar nodes.
Reversed halo sign	The reversed halo sign is a focal rounded area of ground-glass opacity surrounded by a more or less complete ring of consolidation.
Tree-in-bud sign	The tree-in-bud pattern represents centrilobular branching structures that resemble a budding tree.

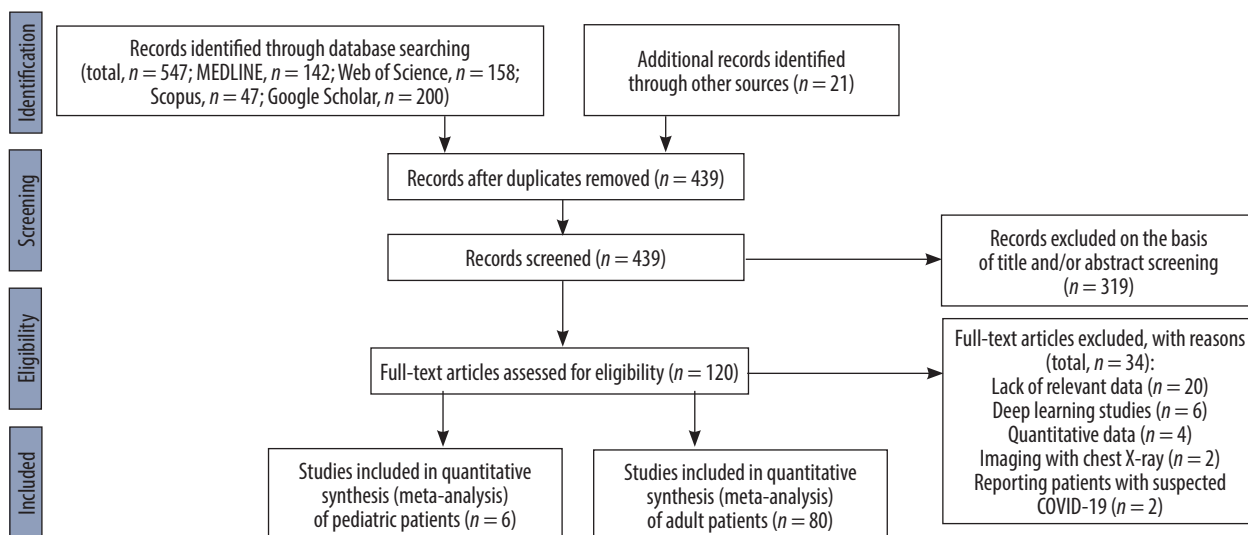


Figure 1. Flow diagram of study selection for systematic review and meta-analysis of computed tomography findings in patients with COVID-19

tative synthesis. Detailed reasons for full-text exclusion are given in Figure 1. With the additional search, 21 new publications were identified, and finally 86 eligible articles were included in the meta-analysis. The total number of

patients who underwent at least one CT scan was 7956. The number of cases with at least one CT imaging ranged from 11 to 975 in different studies. The characteristics of the included studies are provided in Table 2.

Table 2. Characteristics of included studies in this systematic review and meta-analysis

Study	Author	Year	Q/A	Subgroups (if available)	All cases with CT	Ref.
A comparative study of chest computed tomography features in young and older adults with corona virus disease (COVID-19)	Zhu	2020	9		72	[135]
Analysis of factors associated with disease outcomes in hospitalized patients with 2019 novel coronavirus disease	Liu	2020	7		78	[136]
Association of radiologic findings with mortality of patients infected with 2019 novel coronavirus in Wuhan, China	Yuan	2020	8	Reports findings based on outcome (survival or death)	27	[51]
Chest CT features of COVID-19 in Rome, Italy	Caruso	2020	9		60	[137]
Chest CT findings in coronavirus disease-19 (COVID-19): relationship to duration of infection	Bernheim	2020	7		121	[138]
Chest CT findings in patients with corona virus disease 2019 and its relationship with clinical features	Wu	2020	7		80	[139]
Clinical and biochemical indexes from 2019-nCoV infected patients linked to viral loads and lung injury	Liu	2020	5		12	[140]
Clinical and computed tomographic imaging features of novel coronavirus pneumonia caused by SARS-CoV-2	Xu	2020	7	Reports findings based on the severity of disease (mild-moderate or severe-critical)	50	[35]
Clinical and CT imaging features of the COVID-19 pneumonia: focus on pregnant women and children	Liu	2020	6	Reports findings of patients with negative PCR for SARS-CoV-2	34/25 PCR-	[53]
Clinical and high-resolution CT features of the COVID-19 infection: comparison of the initial and follow-up changes	Xiong	2020	6		42	[141]
Clinical and immunologic features in severe and moderate forms of coronavirus disease 2019	Chen	2020	6	Reports findings based on the severity of disease (mild-moderate or severe-critical)	21	[142]
Clinical characteristics and imaging manifestations of the 2019 novel coronavirus disease (COVID-19): a multi-center study in Wenzhou city, Zhejiang, China	Yang	2020	6		149	[143]

Study	Author	Year	Q/A	Subgroups (if available)	All cases with CT	Ref.
Clinical characteristics of 138 hospitalized patients with 2019 novel coronavirus-infected pneumonia in Wuhan, China	Wang	2020	7		138	[144]
Clinical characteristics of 140 patients infected with SARS-CoV-2 in Wuhan, China	Zhang	2020	7	Reports findings based on the severity of disease (mild-moderate or severe-critical)	135	[37]
Clinical characteristics of 24 asymptomatic infections with COVID-19 screened among close contacts in Nanjing, China	Hu	2020	6		24	[83]
Clinical characteristics of 30 medical workers infected with new coronavirus pneumonia	Liu	2020	5		30	[145]
Clinical characteristics of coronavirus disease 2019 in China	Guan	2020	8	Reports findings based on the severity of disease (mild-moderate or severe-critical)	975	[38]
Clinical characteristics of COVID-19-infected cancer patients: a retrospective case study in three hospitals within Wuhan, China	Zhang	2020	7		28	[146]
Clinical characteristics of imported cases of COVID-19 in Jiangsu province: a multicenter descriptive study	Wu	2020	6		80	[147]
Clinical characteristics of novel coronavirus cases in tertiary hospitals in Hubei province	Liu	2020	6		137	[148]
Clinical course and risk factors for mortality of adult inpatients with COVID-19 in Wuhan, China: a retrospective cohort study	Zhou	2020	8	Reports findings based on outcome (survival or death)	191	[149]
Clinical features and chest CT manifestations of coronavirus disease 2019 (COVID-19) in a single-center study in Shanghai, China	Cheng	2020	7	Reports findings of patients with negative PCR for SARS-CoV-2	11/22 PCR-	[59]
Clinical features and short-term outcomes of 102 patients with corona virus disease 2019 in Wuhan, China	Cao	2020	7	CT or CXR	102	[150]
Clinical features and treatment of COVID-19 patients in northeast Chongqing	Wan	2020	7	Reports findings based on the severity of disease (mild-moderate or severe-critical)	135	[40]
Clinical features of 85 fatal cases of COVID-19 from Wuhan: a retrospective observational study	Du	2020	7		80	[151]
Clinical features of patients infected with 2019 novel coronavirus in Wuhan, China	Huang	2020	6		41	[12]
Comparison of hospitalized patients with acute respiratory distress syndrome caused by COVID-19 and H1N1	Tang	2020	7	Reports findings of patients with negative PCR for SARS-CoV-2	73/ 75 PCR-	[60]
Comparison of the clinical characteristics between RNA positive and negative patients clinically diagnosed with 2019 novel coronavirus pneumonia	Li	2020	6	Reports findings of patients with negative PCR for SARS-CoV-2	31/ 23 PCR-	[54]
Coronavirus disease 2019 (COVID-19): role of chest CT in diagnosis and management	Li	2020	6		51	[152]
Coronavirus disease 2019: initial chest CT findings	Zhou	2020	9		62	[153]
CT features of coronavirus disease 2019 (COVID-19) pneumonia in 62 patients in Wuhan, China	Zhou	2020	7		62	[154]
CT image visual quantitative evaluation and clinical classification of coronavirus disease (COVID-19)	Li	2020	9	Reports findings based on the severity of disease (mild-moderate or severe-critical)	78	[42]
CT imaging features of 2019 novel coronavirus (2019-nCoV)	Chung	2020	5		21	[19]
CT manifestations of coronavirus disease-2019: a retrospective analysis of 73 cases by disease severity	Liu	2020	9	Reports findings based on the severity of disease (mild-moderate or severe-critical)	73	[43]

Study	Author	Year	Q/A	Subgroups (if available)	All cases with CT	Ref.
Diagnosis of the coronavirus disease (COVID-19): rRT-PCR or CT?	Long	2020	9	Reports findings of patients with negative PCR for SARS-CoV-2	36/51 PCR-	[58]
Early clinical and CT manifestations of coronavirus disease 2019 (COVID-19) pneumonia	Han	2020	8		108	[155]
Emerging 2019 novel coronavirus (2019-nCoV) pneumonia	Song	2020	6		51	[156]
Epidemiologic and clinical characteristics of 91 hospitalized patients with COVID-19 in Zhejiang, China: a retrospective, multi-centre case series	Qian	2020	7		91	[157]
Epidemiological and clinical characteristics of 99 cases of 2019 novel coronavirus pneumonia in Wuhan, China: a descriptive study	Chen	2020	8		99	[13]
Epidemiological, clinical characteristics of cases of SARS-CoV-2 infection with abnormal imaging findings	Zhang	2020	8		645	[158]
High-resolution computed tomography manifestations of COVID-19 infections in patients of different ages	Chen	2020	8		98	[159]
High-resolution CT features of 17 cases of corona virus disease 2019 in Sichuan province, China	Zhang	2020	7		17	[160]
Imaging and clinical features of patients with 2019 novel coronavirus SARS-CoV-2	Xu	2020	9		90	[161]
Imaging features of coronavirus disease 2019 (COVID-19): evaluation on thin-section CT	Guan	2020	8		53	[162]
Imaging manifestations and diagnostic value of chest CT of coronavirus disease 2019 (COVID-19) in the Xiaogan area	Wang	2020	8		114	[163]
Initial clinical features of suspected coronavirus disease 2019 in two emergency departments outside of Hubei, China	Zhu	2020	6	Reports findings of patients with negative PCR for SARS-CoV-2	32/84PCR-	[55]
Initial CT findings and temporal changes in patients with the novel coronavirus pneumonia (2019-nCoV): a study of 63 patients in Wuhan, China	Pan	2020	8		63	[164]
Novel coronavirus pneumonia (COVID-19) CT distribution and sign features	Wu	2020	9		130	[165]
Novel coronavirus pneumonia (COVID-19) progression course in 17 discharged patients: comparison of clinical and thin section CT features during recovery	Han	2020	6		17	[166]
Performance of radiologists in differentiating COVID-19 from viral pneumonia on chest CT	Bai	2020	8	Reports findings of patients with negative PCR for SARS-CoV-2	219/205 PCR-	[56]
Radiological findings from 81 patients with COVID-19 pneumonia in Wuhan, China: a descriptive study	Shi	2020	9		81	[167]
Relation between chest CT findings and clinical conditions of coronavirus disease (COVID-19) pneumonia: a multicenter study	Zhao	2020	9	Reports findings based on the severity of disease (mild-moderate or severe-critical)	101	[48]
Risk factors associated with disease progression in a cohort of patients infected with the 2019 novel coronavirus	Zhou	2020	5		17	[168]
Sensitivity of chest CT for COVID-19: comparison to RT-PCR	Fang	2020	7		51	[67]
Temporal changes of CT findings in 90 patients with COVID-19 pneumonia: a longitudinal study	Wang	2020	9		90	[85]
The characteristics and clinical value of chest CT images of novel coronavirus pneumonia	Zhao	2020	6		80	[169]
The clinical and chest CT features associated with severe and critical COVID-19 pneumonia	Li	2020	9	Reports findings based on the severity of disease (mild-moderate or severe-critical)	90	[46]

Study	Author	Year	Q/A	Subgroups (if available)	All cases with CT	Ref.
Time course of lung changes on chest CT during recovery from 2019 novel coronavirus (COVID-19) pneumonia	Pan	2020	8		24	[170]
Clinical and CT features in pediatric patients with COVID-19 infection: different points from adults	Xia	2020	6	Paediatrics	20	[29]
Clinical analysis of 31 cases of 2019 novel coronavirus infection in children from six provinces (autonomous region) of northern China	Wang	2020	7	Paediatrics	30	[26]
Analysis of CT features of 15 children with 2019 novel coronavirus infection	Feng	2020	5	Paediatrics	15	[30]
Clinical characteristics of children with coronavirus disease 2019 in Hubei, China	Zheng	2020	5	Paediatrics	25	[28]
Analysis on the clinical characteristics of 36 cases of novel coronavirus pneumonia in Kunming	Fu	2020	6		36	[171]
Association of cardiovascular manifestations with in-hospital outcomes in patients with COVID-19: a hospital staff data	Liu	2020	6		41	[172]
Clinical characteristics of 36 non-survivors with COVID-19 in Wuhan, China	Huang	2020	6	Reports findings based on outcome (survival or death)	32	[173]
Clinical characteristics of 51 patients discharged from hospital with COVID-19 in Chongqing, China	Liu	2020	7	Reports findings based on the severity of disease (mild-moderate or severe-critical)	51	[47]
Clinical characteristics of deceased patients infected with SARS-CoV-2 in Wuhan, China	Li	2020	7	Reports findings based on outcome (survival or death)	161	[50]
Clinical features and laboratory inspection of novel coronavirus pneumonia (COVID-19) in Xiangyang, Hubei	Cao	2020	8	Reports findings based on the severity of disease (mild-moderate or severe-critical)	128	[39]
Clinical features of 81 hospitalized patients with 2019 novel coronavirus-infected pneumonia in Jingzhou, China: a descriptive study	Zhang	2020	7	Reports findings based on the severity of disease (mild-moderate or severe-critical)	81	[41]
Clinical features of patients infected with the 2019 novel coronavirus (COVID-19) in Shanghai, China	Cao	2020	8		198	[174]
Clinical outcomes of patients with 2019-nCoV: a preliminary summary	Zhao	2020	7		118	[175]
Comparison of epidemiological and clinical features of patients with coronavirus disease (COVID-19) in Wuhan and outside Wuhan, China	Lei	2020	5		20	[176]
Coronavirus disease 2019 (COVID-19) pneumonia: early stage chest CT imaging features and clinical relevance	Lu	2020	6		91	[177]
Early prediction of disease progression in 2019 novel coronavirus pneumonia patients outside Wuhan with CT and clinical characteristics	Feng	2020	7		141	[178]
Epidemiological and clinical characteristics of 17 hospitalized patients with 2019 novel coronavirus infections outside Wuhan, China	Li	2020	7		17	[179]
Epidemiological and clinical features of 2019-nCoV acute respiratory disease cases in Chongqing municipality, China: a retrospective, descriptive, multiple-center study	Qi	2020	8	Reports findings based on the severity of disease (mild-moderate or severe-critical)	267	[44]
Epidemiological and clinical features of 291 cases with coronavirus disease 2019 in areas adjacent to Hubei, China: a double-center observational study	Chen	2020	7		291	[180]

Study	Author	Year	Q/A	Subgroups (if available)	All cases with CT	Ref.
How to differentiate COVID-19 pneumonia from heart failure with computed tomography at initial medical contact during epidemic period	Zhu	2020	9		12	[181]
Imaging profile of the COVID-19 infection: radiologic findings and literature review	Ng	2020	5		21	[182]
Key points of clinical and CT imaging features of 2019 novel coronavirus (2019-nCoV) imported pneumonia based on 21 cases analysis	Xu	2020	6	Reports findings based on the severity of disease (mild-moderate or severe-critical)	21	[45]
Prevalence and clinical features of 2019 novel coronavirus disease (COVID-19) in the fever clinic of a teaching hospital in Beijing: a single-center, retrospective study	Liang	2020	5	Reports findings of patients with negative PCR for SARS-CoV-2	20/67 PCR–	[57]
Transmission and clinical characteristics of coronavirus disease 2019 in 104 outside-Wuhan patients, China	Qiu	2020	8		94	[183]
A retrospective study of the clinical characteristics of COVID-19 infection in 26 children	Tang	2020	5	Paediatrics	26	[27]
Coronavirus disease-19 among children outside Wuhan, China	Chen	2020	6	Paediatrics	31	[25]
A comparative study on the clinical features of COVID-19 pneumonia to other pneumonias	Zhao	2020	9		19	[184]
Analysis of 2019 novel coronavirus infection and clinical characteristics of outpatients: an epidemiological study from the fever clinic in Wuhan, China	Wei	2020	6	Reports findings of patients with negative PCR for SARS-CoV-2	511/296 PCR–	[52]

The proportion of CT scan findings

Normal CT results

Among 80 publications, 58 had reported the number of patients without any abnormal CT findings ($n = 6426$). Pooled prevalence of patients with normal CT was 5% (95% CI: 0.03-0.07; $p < 0.001$; Figure 2). However, for paediatric patients this was higher (40%; 95% CI: 0.27-0.55; $p < 0.001$; Figure 3).

GGO

This is one of the most important CT findings suggestive of SARS-CoV-2 [33, 34]. The number of patients with GGO was reported in 59 studies ($n = 5691$). The pooled prevalence of GGO was 73% (95% CI: 0.67-0.78; $p < 0.001$; Figure 4), which makes it the most common imaging sign in patients with COVID-19. Also, GGO was found in 44% of paediatric patients with COVID-19 (95% CI: 0.26-0.63; $p < 0.001$; $n = 65$ patients; Supplementary Figure 1).

Vascular dilation/thickening

Microvascular and macrovascular dilation is probably due to inflammation and the resulting hyperaemia. Thirteen studies reported this sign, although with different nomenclature (vascular dilation, thickening, and enlargement). The pooled prevalence of this feature among COVID-19

patients was 63% (95% CI: 0.52-0.73; $p < 0.001$; Supplementary Figure 2).

Pattern of involvement

Bilateral involvement of lungs

Fifty-four articles reported bilateral involvement of the lungs ($n = 5250$). The proportion of patients with this feature was 78% (95% CI: 0.73-0.82; $p < 0.001$; Figure 5), which is the most common CT scan pattern found in COVID-19 patients in this meta-analysis. Thirty-two per cent of paediatric patients had this feature in their CT images (95% CI: 0.13-0.53; $p < 0.001$; $n = 102$ patients; Supplementary Figure 1).

Peripheral distribution

Peripheral zone of lungs is generally defined as the outer one-third on lung parenchyma. We found that in 1942 cases, 69% had lesions located in the peripheral zone of the lungs (95% CI: 0.61-0.76; $p < 0.001$; Supplementary Figure 2).

Involvement of more than one lobe

Among the included studies, a few reported detailed information about the number of involved lobes for each patient. However, because other publications just reported the proportion of cases with more than one lobe involvement, we took this as a cut-off for reporting the results. For 1687 cas-

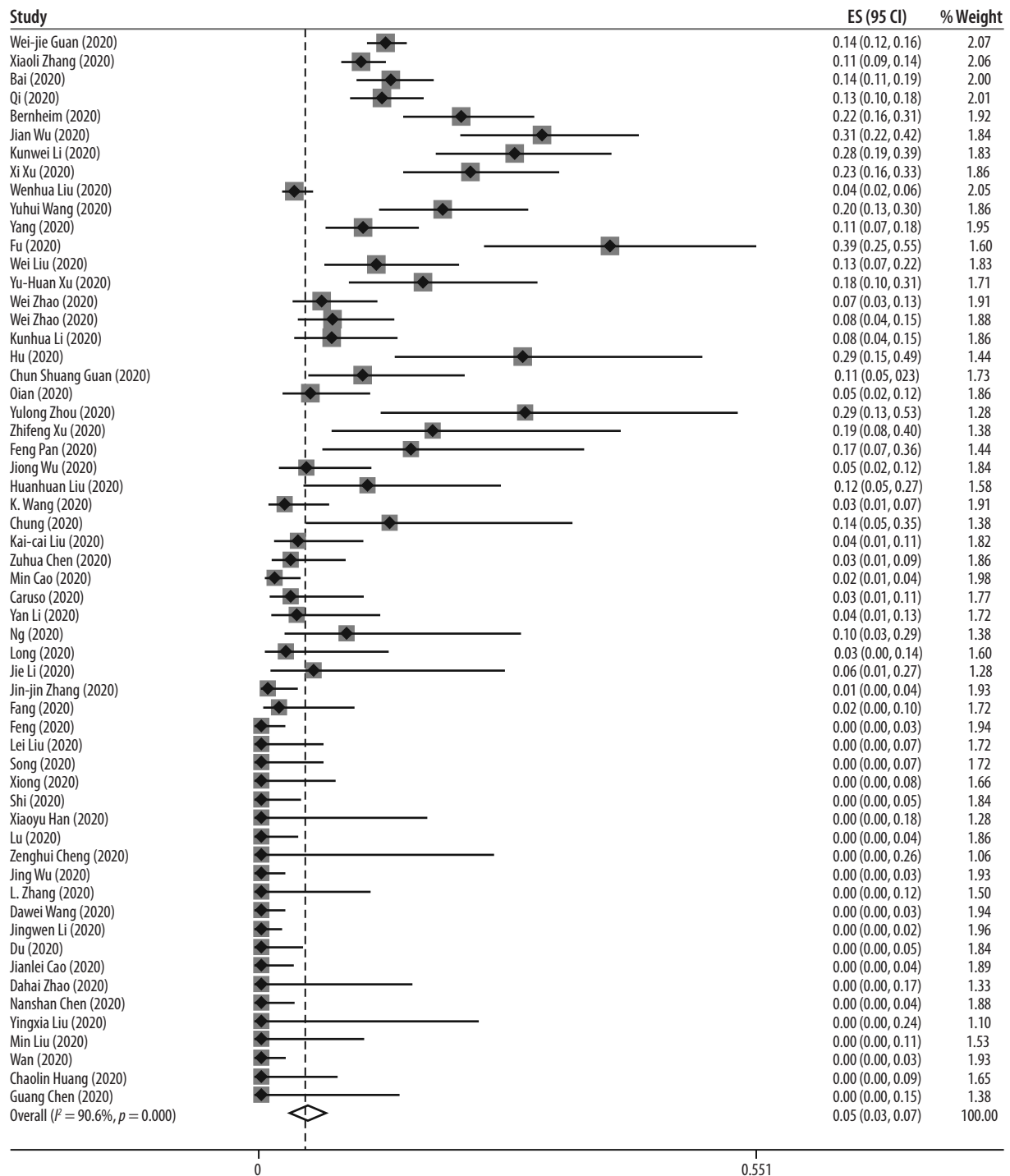


Figure 2. Forest plot for the pooled proportion of adult patients with unremarkable computed tomography findings

es, 75% had involvement of more than one lung lobe, which makes it the second most common pattern of involvement seen in CT images (95% CI: 0.68-0.82; $p < 0.001$; Figure 6).

Location of involved lobes

LLL and RLL were involved in 67% and 66% of patients, respectively. Proportions of patients with LUL, RUL, and RML involvement are provided in Table 3; however, they should be treated with caution due to publication bias.

Other features

Other more common signs we found in our meta-analysis were air-bronchogram (40%), consolidation (34%), crazy-paving pattern or paving stone sign (31%), bronchiectasis (24%), and pleural thickening (24%). No cavitation was reported in patients, and only three of 501 cases had the tree-in-bud sign. The proportion of all extracted signs and patterns, along with 95%CI, I^2 statistics, and p -values for the Egger's test and ES, are provided in Table 3 and Supplementary

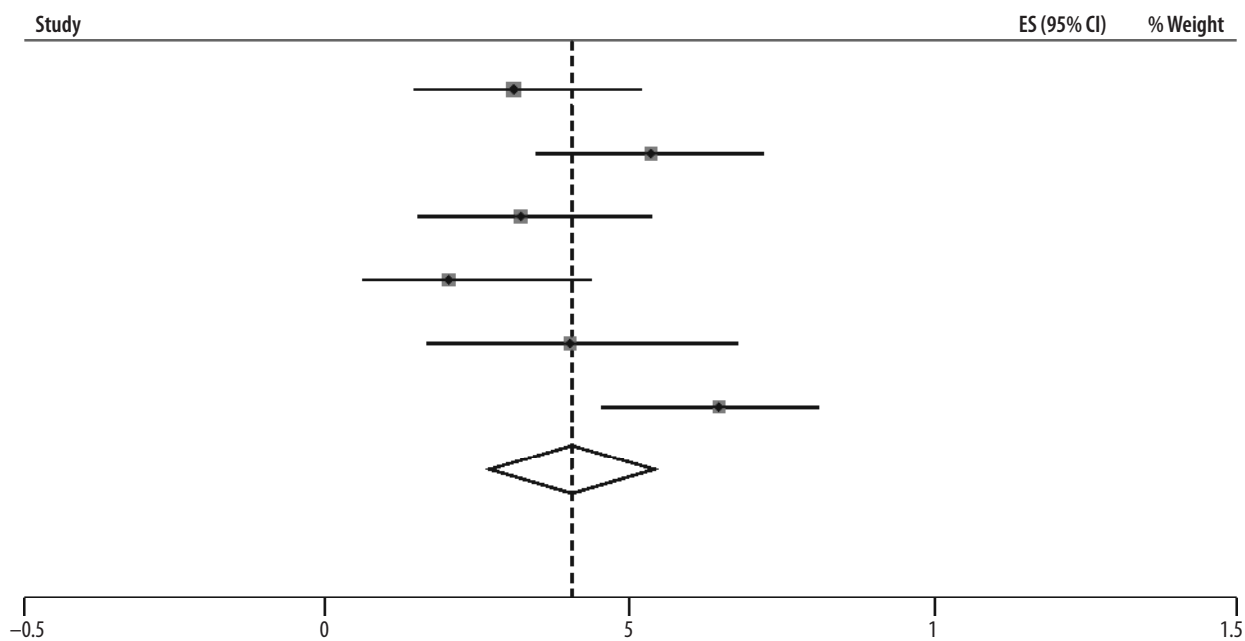


Figure 3. Forest plot for the pooled proportion of paediatric patients with unremarkable computed tomography findings

Figure 2. Statistics on the meta-analyses of paediatric patients are provided in Table 4.

Subgroup analyses

Severity

We found 14 publications that reported CT findings of patients with the severe-critical and mild-moderate disease, separately [35-48]. There were 1707 and 494 patients with mild-moderate and severe-critical situations, respectively. Subgroup analysis of these patients showed that those with severe-critical illness had a higher risk of having bilateral involvement (RR, 1.37; 95 CI: 1.06-1.78; $p = 0.02$; Figure 7) and consolidation (RR, 3.12; 95 CI: 1.57-6.23; $p < 0.001$; Figure 7). Also, the severe-critical group had a lower proportion of patients with normal CT, compared with the mild-moderate group (RR, 0.31; 95 CI: 0.18-0.53; $p < 0.001$). The details of these findings are summarized in Table 5 and Supplementary Figure 3.

Outcome

We found three studies [49-51] comparing CT findings of living and dead COVID-19 patients. It turned out that the presence of GGO is not associated with a worse outcome (RR, 1.97; 95% CI: 0.48-8.00; $p = 0.34$; Figure 8), but bilateral involvement with an increased risk of mortality (RR, 3.19; 95% CI: 1.07-9.49; $p = 0.04$; Table 5 and Figure 8).

Absence of SARS-CoV-2

Nine studies [52-60] compared imaging findings of pneumonia patients with confirmed COVID-19 ($n = 968$) to those without RT-PCR confirmation of the infection with

SARS-CoV-2 ($n = 821$). COVID-19 cases had a higher risk of having GGO (RR, 1.45; 95 CI: 1.13-1.86; $p < 0.001$; Figure 9), but there was no significant difference between the presence of pleural effusion, positive CT findings, and bilateral involvement in two groups. However, non-COVID-19 patients showed an increased risk of having consolidation (RR, 1.23; 95 CI: 1.09-1.39; $p < 0.001$; Figure 9). Detailed information is provided in Table 5 and Supplementary Figures 4 and 5.

Discussion

COVID-19 continues to spread globally as there are thousands of confirmed cases and deaths reported every day and more than 85,000 deaths in 210 countries up to 9 April 2020 [5]. With such a relatively unknown virus causing a pandemic, further studies, data gathering, and evaluation seem necessary. Early and fast detection of present cases, in such conditions with up to 80% prevalence of patients with mild symptoms and asymptomatic carriers [61,62], and long-term stability of the underlying virus on different surfaces [63], leads to better isolation, treatment, and monitoring of patients. This can also improve disease outcomes, reduce costs, and ease the control of this progressing pandemic [64,65].

Chest CT evaluation is one of the most important aspects of the diagnostic process in suspected COVID-19 patients. RT-PCR, currently being the recommended test for laboratory confirmation of the disease [66], has its own limitations, as previously discussed, such as being time consuming and not having adequate sensitivity, especially early in the infection course [67]. As a result, chest CT may become more important in confirming cases in need of hospital admission, isolation, etc. Despite being relatively sensitive in detecting pneumonia patients [67,18], chest CT may not have adequate specificity for COVID-19

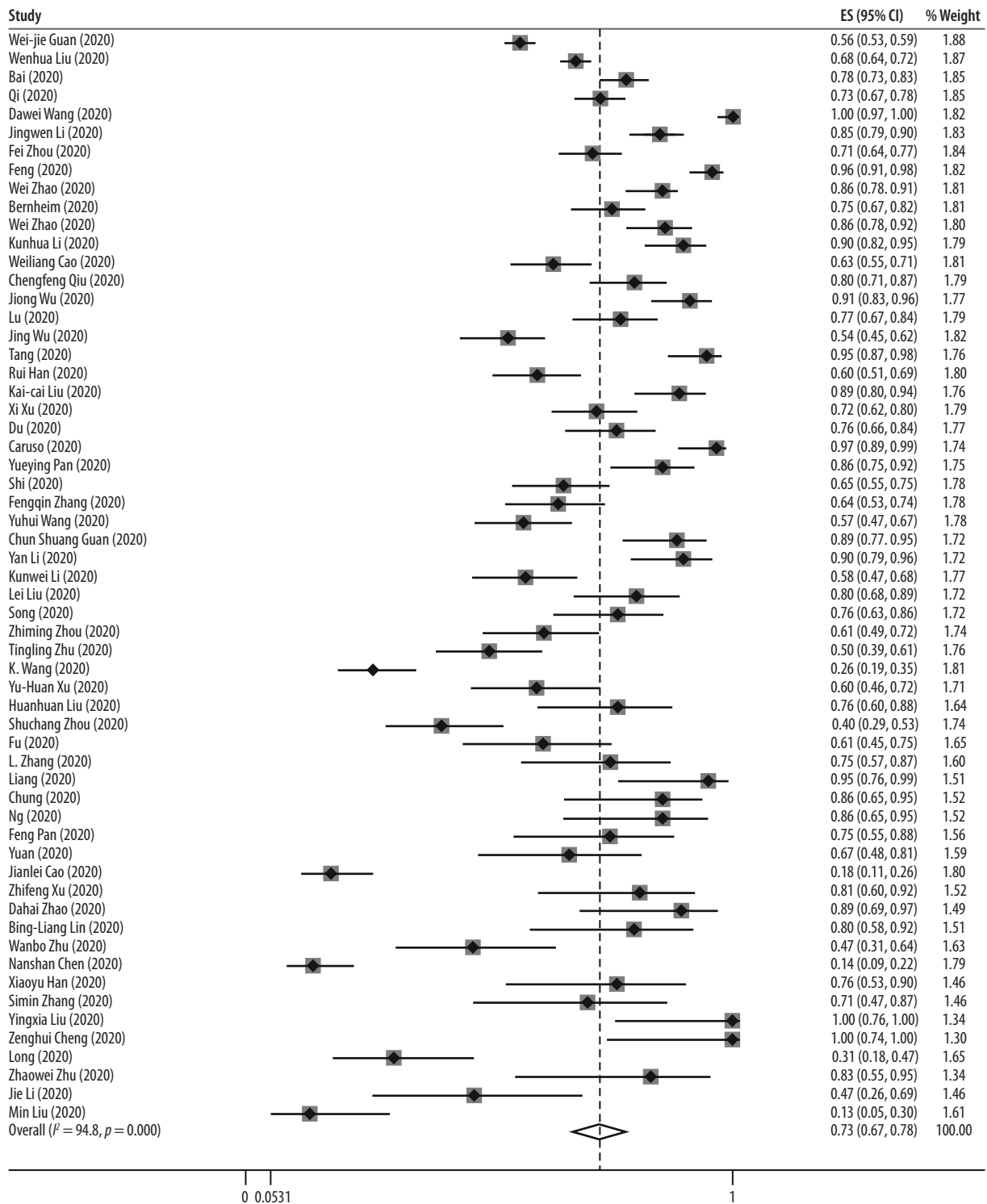


Figure 4. Forest plot for the pooled prevalence of ground-glass opacity in patients with COVID-19

in single images without detailed assessment [68]. In addition, high cost and relatively lower accessibility of chest CT in western countries, as well as development of more rapid RT-PCR testing methods have limited CT use in those regions [69,70]. In order to gather the information needed for accurate evaluation of chest CTs by healthcare providers, we aim to provide a more detailed systematic review of chest CT findings and further evaluate them in specific subgroups.

Overall radiographic features

Normal chest CT was seen in only 5% of our cases. This, along with some other previously published studies, supports the fact that chest CT is a sensitive diagnostic tool that is appropriate for screening suspected patients, especially in epidemics [67,18]. Common findings in viral pneumonias include patchy or diffuse GGOs and reticulations. Consolidations may be present or absent [71].

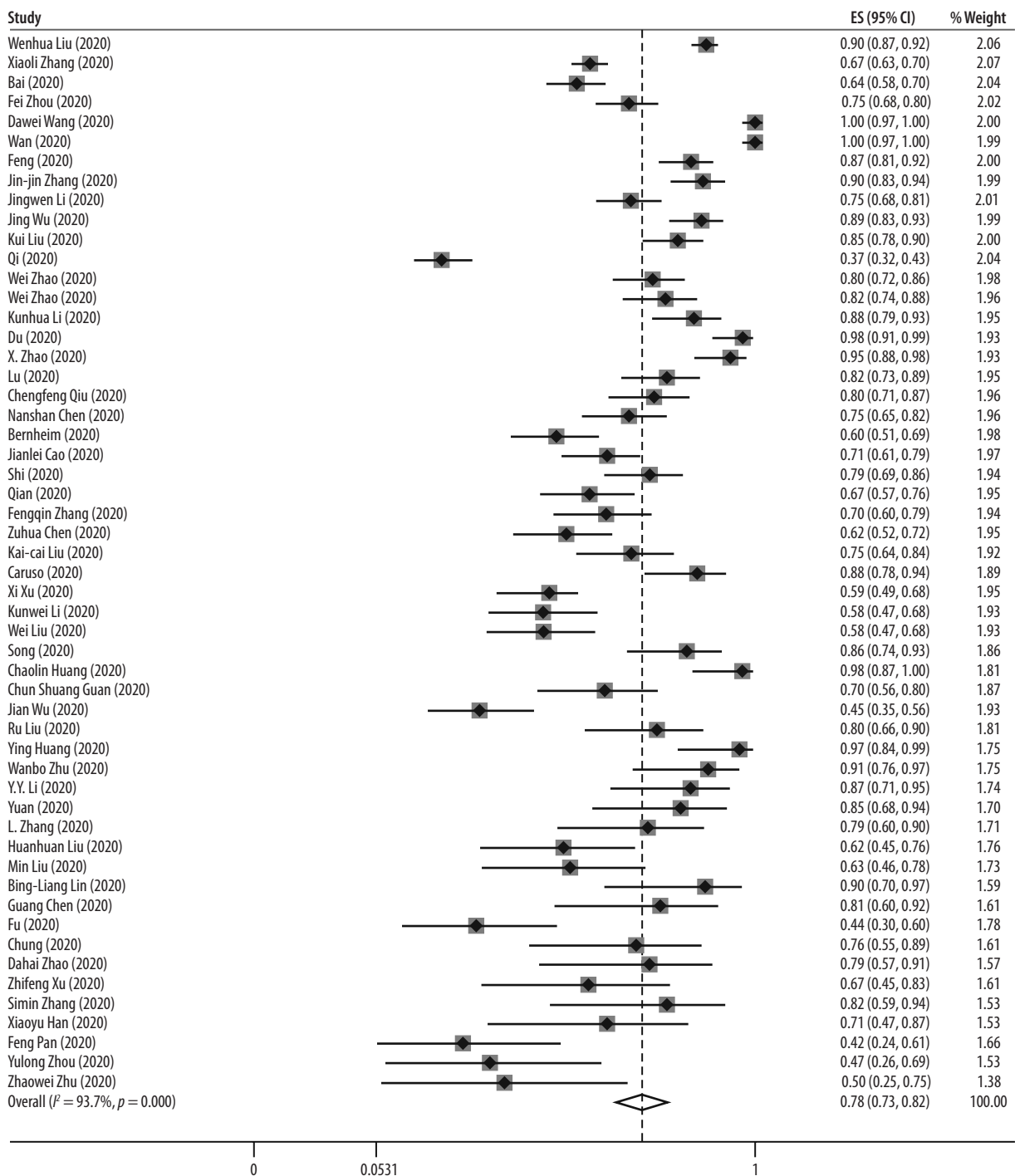


Figure 5. Forest plot for the pooled prevalence of bilateral involvement in patients with COVID-19

Consistent with this phenomenon, our study results show that the most common radiological finding among COVID-19 patients is GGO, followed by vascular thickening (dilation), air bronchogram, and consolidation (observed in 73%, 61%, 41%, and 34% of cases, respectively). Other probable radiologic signs include crazy paving pattern (27%), pleural thickening (24%), bronchiectasis (24%), and halo sign (21%). Pleural effusion, reversed halo sign, and lymphadenopathies were rare, and almost no cases were seen with tree-in-bud sign or cavitations. A relatively low proportion of consolidation positive chest CTs may be

a finding that differentiates SARS-CoV-2 infections from those caused by MERS-CoV and SARS-CoV. Conversely, GGOs are seen commonly in patients infected with all three epidemic-causing coronaviruses [72].

Distribution

Among five lung lobes, the left lower and right lower lobes were more likely to be involved in COVID-19 patients, as seen in 67% and 66% of cases, respectively. The least involved lobe was the right middle lobe. So, the infec-

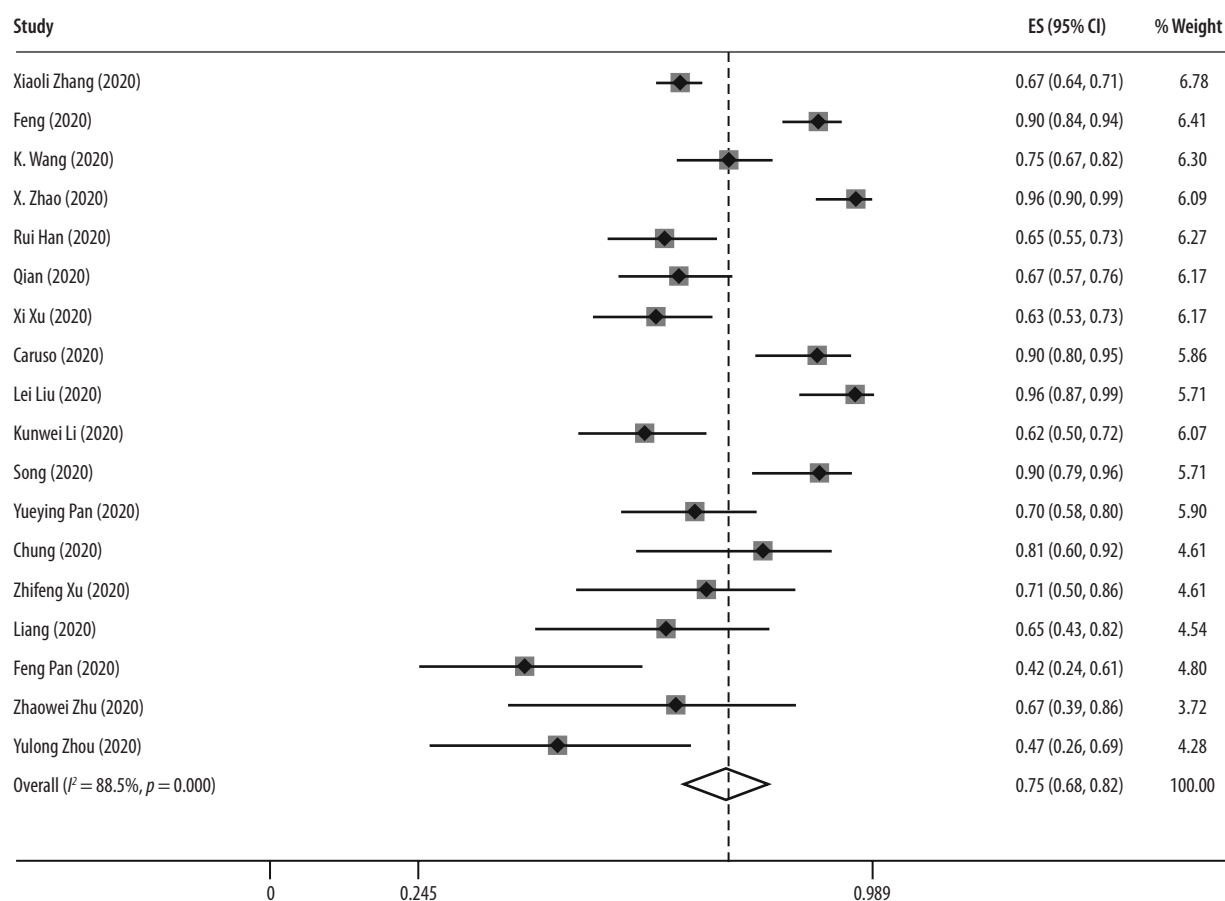


Figure 6. Forest plot for the pooled proportion of patients with more than one lung lobe involvement

tion is more common in the lower lobes, is usually bilateral (78%), and frequently involves more than one lobe (76%) in peripheries (68%). Lesions are usually multifocal (66%), and diffuse distribution (8%) is not common. These findings are also in favour of the distribution patterns proposed previously [73-76].

Concerning the distribution of different lesions observed in COVID-19, peripheral distribution and lower lung infiltrations are the features in common with MERS-CoV and SARS-CoV [72].

Paediatric population

It was previously observed that the disease course might have a milder pattern in children, with a higher proportion of asymptomatic carriers present [77,78]. In our study, a pooled prevalence of 40% was observed for normal chest CTs. Even considering the 95% CI, it is a significantly lower percentage compared with our general population. This implies that chest CT has lower sensitivity for identifying patients in the paediatric group, and relying on chest CT findings may increase the risk of missing patients with normal chest CTs. As a result, and considering the higher proportion of asymptomatic carriers in this age group, an integrated diagnostic approach that relies on thorough examination of clinical findings, exposure history, laboratory

results, imaging, and RT-PCR tests might be a better option in children with suspected novel coronavirus infection. In addition, bilateral and unilateral involvement in chest CT images shows closer proportions in our findings, and GGOs are less common. This can mean that the typical imaging findings in children may also differ from those observed in the general population of COVID-19 patients.

Severity

In this meta-analysis, we tried to evaluate the differences in chest CT findings between the severe/critical group and mild/moderate group, classified based on the Guidelines for the Diagnosis and Treatment of New Coronavirus Pneumonia or the American Thoracic Society guidelines for community-acquired pneumonia.

In our study population for disease severity, 25% of cases were classified as severe/critical, considering the 19% report in a study on 72,314 confirmed and suspected COVID-19 patients in China [79]. According to their chest CT findings, it is inferred that the tendency towards developing consolidations and bilateral infiltrations is higher in patients with severe/critical disease. On the other hand, normal lung CT scan had a higher proportion in the mild/moderate group. Like in severe cases of MERS-CoV and SARS-CoV, pleural effusion is a radiological finding with greater prevalence in

Table 3. Statistics on meta-analysis of pooled prevalence of computed tomographic features in COVID-19 patients

Feature	No. of studies	No. of cases	ES (proportion)	p-value of ES	Lower CI	Upper CI	I ² statistics	p-value of χ^2	p-value of Egger's test
Air bronchogram	24	1714	0.4	< 0.001	0.3	0.51	94.97	0.001	0.412
Bronchial wall thickening	12	1148	0.18	< 0.001	0.07	0.31	96.42	< 0.001	0.963
Bronchiectasis	11	871	0.24	< 0.001	0.12	0.37	94.16	< 0.001	0.967
Bilateral involvement	54	5250	0.78	< 0.001	0.73	0.82	97.5	< 0.001	0.797
Consolidation	46	3881	0.34	< 0.001	0.26	0.42	95.13	< 0.001	0.107
Crazy-paving pattern	21	1564	0.31	< 0.001	0.21	0.42	95.30	< 0.001	0.163
GGO	59	5691	0.73	< 0.001	0.67	0.78	94.76	< 0.001	0.205
Halo sign	6	669	0.21	< 0.001	0.08	0.37	95.29	< 0.001	0.844
Left lower lobe	15	1960	0.67	< 0.001	0.5	0.82	97.85	< 0.001	0.1
Left upper lobe	15	1960	0.54	< 0.001	0.4	0.67	96.72	< 0.001	0.005
Lymphadenopathy	33	2815	0.03	< 0.001	0	0.06	93.18	< 0.001	0.026
> 1 lobe involvement	18	1687	0.75	< 0.001	0.68	0.82	88.53	< 0.001	0.619
Normal CT	58	6426	0.05	< 0.001	0.03	0.07	90.58	< 0.001	0.395
Pleural effusion	41	3483	0.04	< 0.001	0.03	0.06	72.47	< 0.001	0.802
Peripheral distribution	29	1942	0.69	< 0.001	0.61	0.76	91.44	< 0.001	0.907
Pleural thickening	11	1423	0.24	< 0.001	0.12	0.38	96.8	< 0.001	0.591
Reversed-halo sign	5	649	0.05	0.001	0.02	0.1	77.3	< 0.001	0.633
Right lower lobe	15	1960	0.66	< 0.001	0.5	0.8	97.71	< 0.001	0.139
Right middle lobe	15	1960	0.42	< 0.001	0.31	0.54	95.58	< 0.001	0.002
Right upper lobe	15	1960	0.5	< 0.001	0.37	0.64	96.55	< 0.001	0.002
Tree-in-bud sign	7	501	0	0.97	0	0.01	0	< 0.001	0.248
Vascular dilation/thickening	13	1123	0.63	< 0.001	0.52	0.73	92.23	< 0.001	0.971
Cavitation	13	953	0	–	–	–	–	–	–

Table 4. Statistics on meta-analysis of pooled prevalence of computed tomographic features in paediatric COVID-19 patients

Feature	No. of studies	No. of cases	ES (proportion)	p-value of ES	Lower CI	Upper CI	I ² statistics	p-value of χ^2	p-value of Egger's test
Normal CT	6	147	0.4	0.01	0.27	0.55	64.72	0.01	0.233
Bilateral	4	102	0.32	0.002	0.13	0.53	79.35	< 0.001	0.124
GGO	3	65	0.44	0.112	0.26	0.63	54.3	0.11	0.511

severe/critical SARS-CoV-2 infection [72]. This, combined with the clinical and laboratory data, may help in the classification of patients into severity groups and guide clinicians in choosing the subsequent plans accordingly.

Outcome

Other than diagnostic values of chest CT, its findings might be useful in predicting disease outcomes and patient prognoses in COVID-19. Regarding the outcome, bilateral involvement of lung parenchyma was associated with a higher risk of mortality. This finding is in accordance with the reports of a recent preprint article showing

that the elevated level of inflammatory cytokines (CCL7, CXCL10, and IL-1 receptor antagonist) is associated with the extent of lung injury and a fatal outcome [80].

Pneumonia patients without confirmed SARS-CoV-2 infection

In this subgroup meta-analysis, we compared chest CT findings in confirmed COVID-19 pneumonia cases with the negative-PCR group, including suspected patients without PCR confirmations and non-COVID pneumonias such as H1N1 influenza infection [81]. Consolidation, which was observed more commonly in severe/

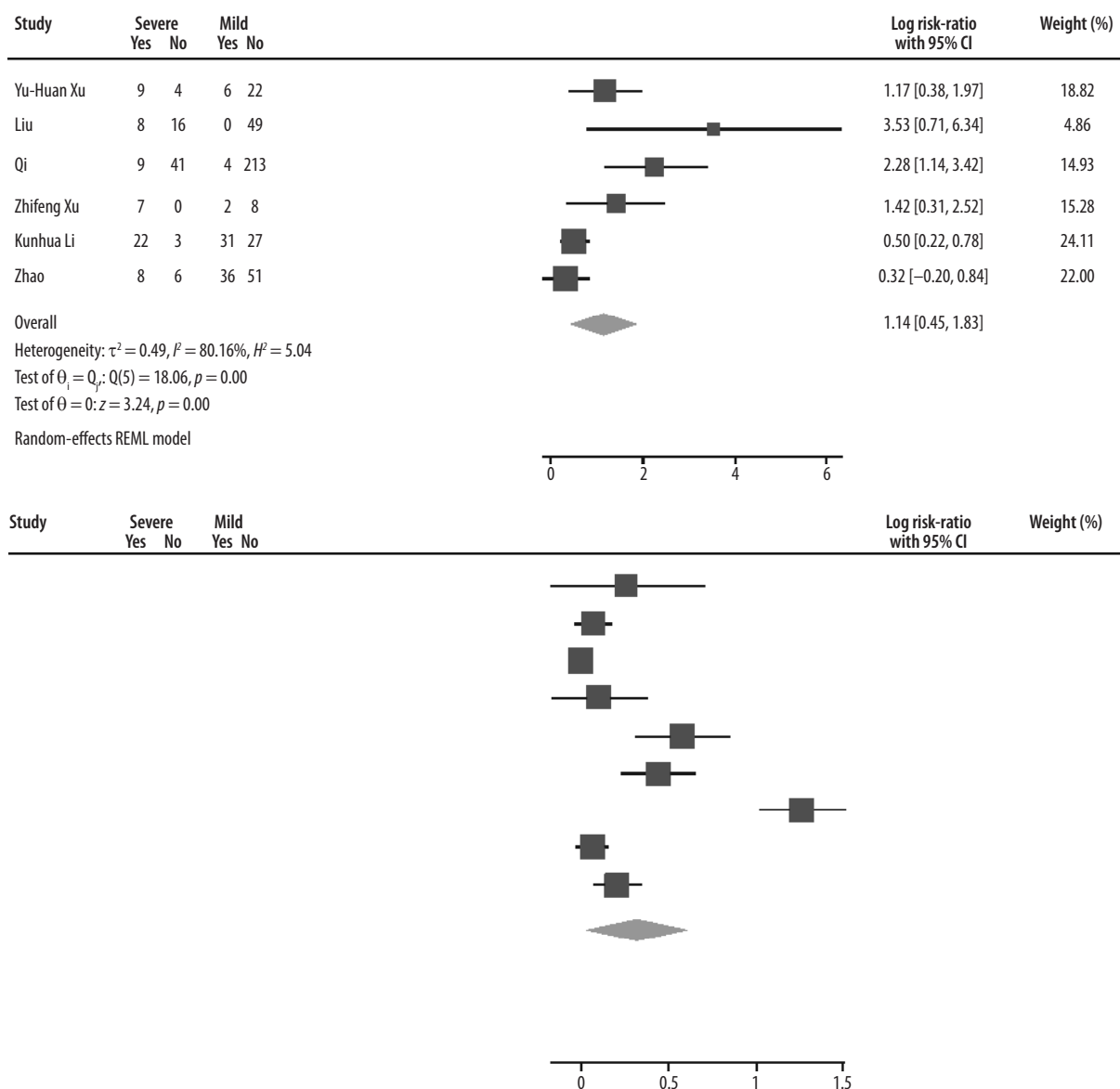


Figure 7. Forest plot comparing the prevalence of consolidation (up) and bilateral involvement (down) between severe-critical and mild-moderate patients. REML – restricted maximum likelihood

critical patients than in mild/moderate ones, had a higher chance for development in non-COVID pneumonias. In other words, the interpretation for observing consolidations in chest CTs depends on the groups we want to differentiate. If severity of the COVID-19 pneumonia is the question, consolidation favours severe/critical disease. Despite that, if we are going to differentiate COVID-19 pneumonias from non-COVID ones, consolidations in chest CT images make COVID-19 diagnosis less likely. After all, other diagnostic methods may be useful in differentiating such conditions.

Asymptomatic infection

CT abnormalities can also be present in COVID-19 patients without clinical symptoms. Wang *et al.* reported that 37 of 55 asymptomatic patients (67.2%) had abnormalities in their chest CT scans [82]. Similar observations were reported in two other studies, in which 17 of 24 [83]

and 12 of 13 [84] asymptomatic patients had positive CT results (70.8% and 92.3%, respectively). However, due to insufficient data, we could not perform a meta-analysis of the imaging features of asymptomatic patients.

Limitations

This systematic review has several limitations. The interval between the initiation of clinical symptoms and the acquisition of the first CT scan is an important factor because the evolution of lesions seems to occur after the early phase of the disease [85]. However, due to significant heterogeneity among the “first symptom first-CT” intervals in different studies, we did not consider this in our meta-analysis. Moreover, for the definitions of chest CT features, some studies used the Glossary of Terms for Thoracic Imaging by the Fleischner Society [86], but others just reported the findings without an exact denotation. Unfortunately, we also did not consider the underlying

Table 5. Statistics on subgroup analysis of COVID-19 patients, based on severity, outcome, and PCR results

Subgroup	No. of cases (events/participants)		Feature	No. of studies	ES (RR)	p-value of ES	Lower CI	Upper CI	I ² statistics (%)
	Severe-critical	Mild-moderate							
Severity				14					
	245/264	447/710	Bilateral involvement	9	1.38	0.02	1.06	1.79	97.36
	268/356	890/1410	GGO	9	1.13	0.02	1.02	1.26	74.02
	9/383	196/1459	Normal CT	11	0.31	< 0.001	0.18	0.54	-50.14
	63/133	79/449	Consolidation	6	3.13	< 0.001	1.57	6.23	80.16
	25/118	12/312	Pleural effusion	6	7.77	< 0.001	3.97	15.18	40.74
PCR results	COVID-19	Non-COVID-19		9					
	703/827	431/606	Bilateral involvement	5	1.20	0.24	0.89	1.60	94.57
	241/937	283/798	consolidation	8	0.81	< 0.001	0.71	0.91	42.6
	688/937	410/798	GGO	8	1.45	< 0.001	1.13	1.86	89.59
	39/843	114/656	Pleural effusion	6	0.47	0.12	0.18	1.22	77.04
	814/853	632/701	Positive CT	6	1.03	0.59	0.92	1.15	93.13
	57/66	72/114	Peripheral distribution	3	1.42	0.28	0.75	2.69	92.21
	153/843	99/656	Lymphadenopathy	6	0.55	0.18	0.23	1.3	56.08
Outcome	GGO+	GGO-							
	115	14	Death	3	1.97	0.34	0.48	8	77.75
	176	74	Survival						
	Bilateral+	Bilateral-							
	117	12	Death	3	3.18	0.04	1.07	9.49	58.99
	170	80	Survival						

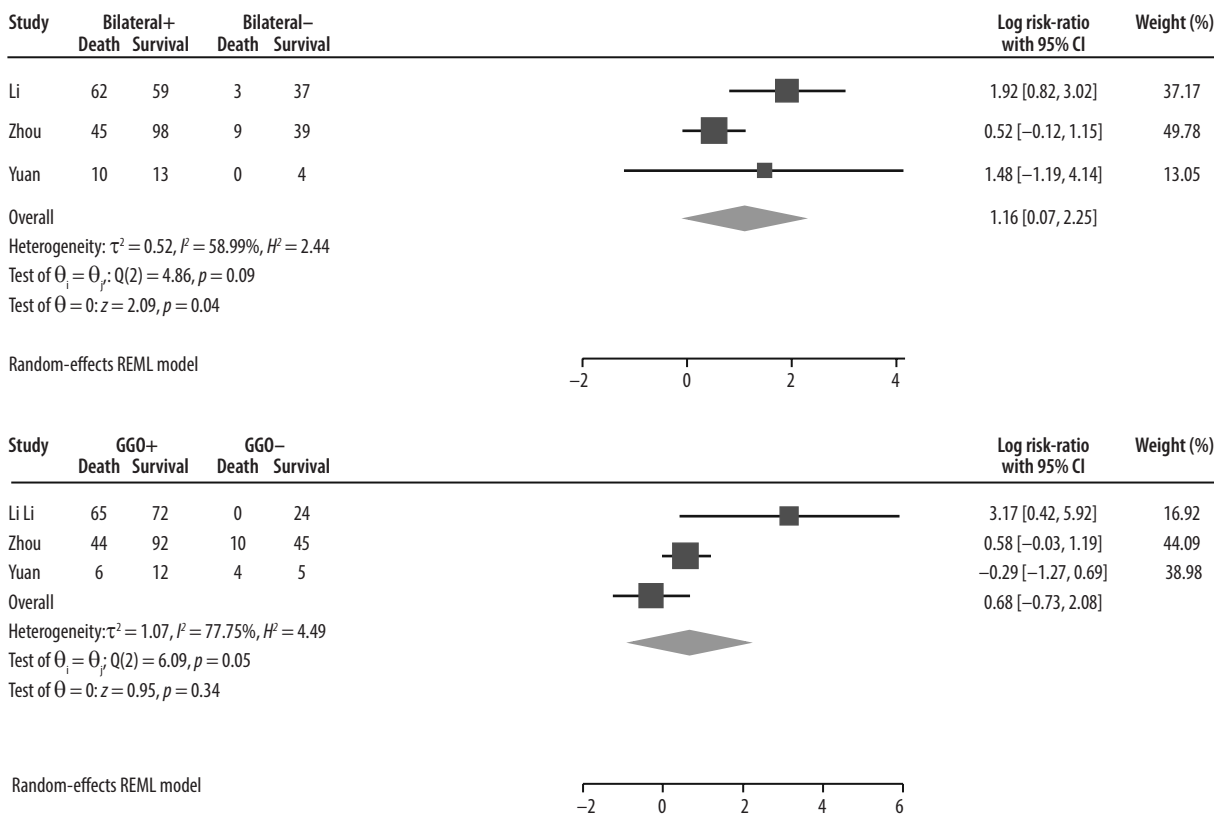
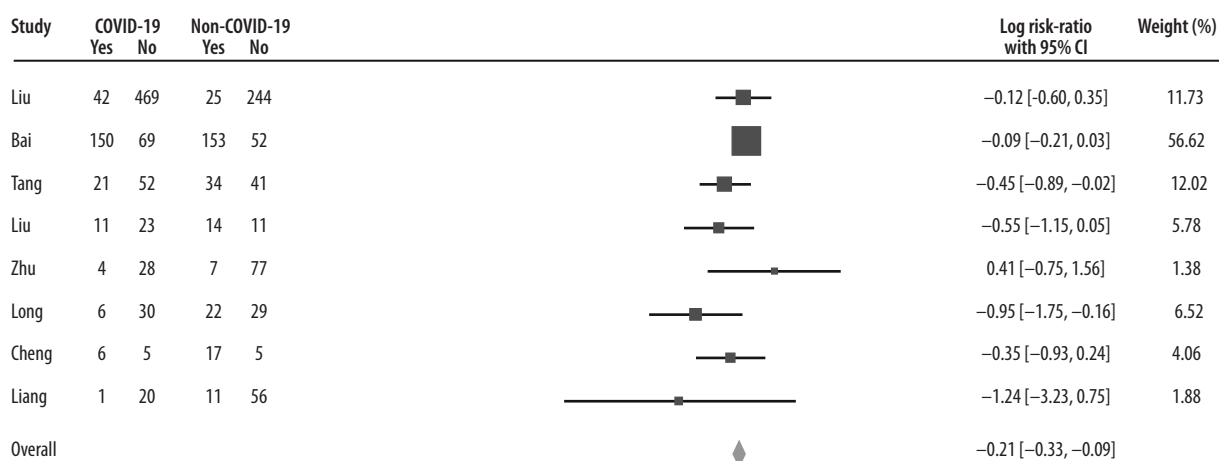
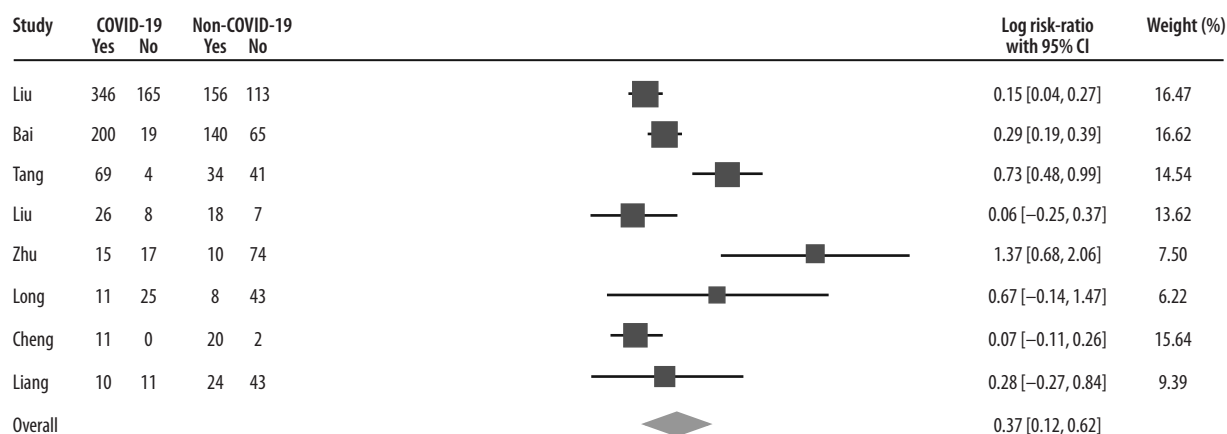



Figure 8. Forest plot comparing the mortality rate between patients with and without bilateral involvement (up), and with and without ground-glass opacities (down)



Heterogeneity: $I^2 = 42.60\%$, $H^2 = 1.74$
 Test of $\theta = \theta_0$: $Q(7) = 12.20$, $p = 0.09$
 Test of $\theta = 0$: $Z = -3.39$, $p = 0.00$

Fixed-effects Mantel-Haenszel model



Heterogeneity: $\tau^2 = 0.10$, $I^2 = 89.59\%$, $H^2 = 9.60$
 Test of $\theta = \theta_0$: $Q(7) = 33.23$, $p = 0.00$
 Test of $\theta = 0$: $Z = 2.89$, $p = 0.00$

Random-effects REML model




Figure 9. Forest plot comparing the incidence of consolidation (up) and GGO (down), between patients with and without COVID-19

conditions and risk factors of patients, which are shown to be important prognostic factors [49,87]. Regarding paediatric patients, there were only six publications that had reported CT findings of 147 paediatric patients separately. Another limitation of this meta-analysis is that the follow-up duration of three publications comparing survivors and deceased patients was also different. Now, there are more than 100000 cases of COVID-19 in the USA, Spain, Italy, Germany, and France, but most of the included publications in this meta-analysis belong to China. In addition, for the calculation of the prevalence of bilateral involvement, we had to impute the number of cases for a few studies. This was because such papers reported only the numbers of patients with positive CT

findings and those with unilateral involvement. As a result, we presumed bilateral involvement to be equal to the difference between these two values. It is worth mentioning that the results of this meta-analysis are all based on the proportion of patients with different CT features. During the full-text screening, we found some studies with quantitative reports of CT findings (e.g. CT scores, the total number of lesions and involved segments, the volume of involved lung tissue, etc.), but because of the extreme heterogeneity of scales and reporting methods, we did not include them in the analysis. Among the 86 included studies, most are retrospective. This implies the urgent need for more prospective cohort studies with control of confounding factors, which hopefully will result in a more

accurate comparison of clinical and imaging features. Finally, the potential correlation between CT symptoms within each patient would imply the importance of the reader experience and performance. However, the available evidence is not sufficient to analyse the effect of the learning curve in this regard.

Conclusions

The pandemic of COVID-19 [88,89] has posed challenges to health care systems [90] with prevention [91,92], diagnosis [93], treatment [91,94-104], and management [99,105,106] in both adult and paediatric settings [107]. Recent research could improve our understanding of immunopathogenesis [96,97,101,102,108-120,] and proximal origin of the virus [121,122]. However, no specific treatment and prevention has been developed, and the pandemic continues to affect multiple organs and systems and people of diverse immunogenetic background [109, 111,113,114,118,123-128].

In conclusion, chest CT can be a relatively sensitive and fast tool for distinguishing COVID-19 in the adult population. However, because of the relatively low inci-

dence of pulmonary lesions detectable by CT, it might not be an appropriate diagnostic tool for paediatrics. SARS-CoV-2-infected patients show different patterns of lung involvement in the chest CT images, with similarities and differences with other viral types of pneumonia. Regarding what we observed, COVID-19 patients most commonly present with GGO, with or without air bronchogram and consolidations, with the lower lobes being more dominantly involved. Further studies are required for a more accurate interpretation of CT features in patients with COVID-19 concerning disease severity and outcomes. Also, given the risk of re-infection [129], it would be interesting to compare CT findings between people with first infection and people with re-infection. Scientific collaboration with systemic knowledge production [130-133] is needed in such a critical condition [134] to deal effectively with a pandemic that has caused changes to the humanity in numerous dimensions [185].

Conflicts of interest

The authors report no conflict of interest.

References

1. The Lancet. Emerging understandings of 2019-nCoV. *Lancet* 2020; 395: 311.
2. Tang Q, Song Y, Shi M, et al. Inferring the hosts of coronavirus using dual statistical models based on nucleotide composition. *Sci Rep* 2015; 5: 17155.
3. Gorbalenya AE, Baker SC, Baric RS, et al. Severe acute respiratory syndrome-related coronavirus: the species and its viruses – a statement of the Coronavirus Study Group. *bioRxiv*: 2020.2002.2007.937862. doi: 10.1101/2020.02.07.937862.
4. WHO. Rolling updates on coronavirus disease (COVID-19). 2020. Available at: <https://www.who.int/emergencies/diseases/novel-coronavirus-2019/events-as-they-happen>.
5. WHO. Coronavirus disease (COVID-2019) situation report 80. 2020. Available at: https://www.who.int/docs/default-source/coronaviruse/situation-reports/20200409-sitrep-80-covid-19.pdf?sfvrsn=1b685d64_2.
6. Ksiazek TG, Erdman D, Goldsmith CS, et al. A novel coronavirus associated with severe acute respiratory syndrome. *N Engl J Med* 2003; 348: 1953-1966.
7. Drosten C, Gunther S, Preiser W, et al. Identification of a novel coronavirus in patients with severe acute respiratory syndrome. *N Engl J Med* 2003; 348: 1967-1976.
8. Kuiken T, Fouchier RA, Schutten M, et al. Newly discovered coronavirus as the primary cause of severe acute respiratory syndrome. *Lancet* 2003; 362: 263-270.
9. de Wit E, van Doremalen N, Falzarano D, Munster VJ. SARS and MERS: recent insights into emerging coronaviruses. *Nat Rev Microbiol* 2016; 14: 523-534.
10. Al-Tawfiq JA, Gautret P. Asymptomatic Middle East Respiratory Syndrome Coronavirus (MERS-CoV) infection: extent and implications for infection control: a systematic review. *Travel Med Infect Dis* 2019; 27: 27-32.
11. Baharoon S, Memish ZA. MERS-CoV as an emerging respiratory illness: a review of prevention methods. *Travel Med Infect Dis* 2019; 32: 101520.
12. Huang C, Wang Y, Li X, et al. Clinical features of patients infected with 2019 novel coronavirus in Wuhan, China. *Lancet* 2020; 395: 497-506.
13. Chen N, Zhou M, Dong X, et al. Epidemiological and clinical characteristics of 99 cases of 2019 novel coronavirus pneumonia in Wuhan, China: a descriptive study. *Lancet* 2020; 395: 507-513.
14. Chan JF, Yuan S, Kok KH, et al. A familial cluster of pneumonia associated with the 2019 novel coronavirus indicating person-to-person transmission: a study of a family cluster. *Lancet* 2020; 395: 514-523.
15. Bonilla-Aldana DK, Quintero-Rada K, Montoya-Posada JP, et al. SARS-CoV, MERS-CoV and now the 2019-novel CoV: have we investigated enough about coronaviruses? – A bibliometric analysis. *Travel Med Infect Dis* 2020; 33: 101566.
16. Sun P, Qie S, Liu Z, et al. Clinical Characteristics of 5732 Patients with 2019-nCoV Infection. 2020. Available at: <https://ssrn.com/abstract=3539664> or <http://dx.doi.org/10.2139/ssrn.3539664>.
17. Yang Y, Yang M, Shen C, et al. Evaluating the accuracy of different respiratory specimens in the laboratory diagnosis and monitoring the viral shedding of 2019-nCoV infections. 2020. DOI: 10.1101/2020.02.11.20021493.

18. Ai T, Yang Z, Hou H, et al. Correlation of chest CT and RT-PCR testing in coronavirus disease 2019 (COVID-19) in China: a report of 1014 cases. *Radiology* 2020; 296: E32-E40.
19. Chung M, Bernheim A, Mei X, et al. CT imaging features of 2019 novel coronavirus (2019-nCoV). *Radiology* 2020; 295: 202-207.
20. Liberati A, Altman DG, Tetzlaff J, et al. The PRISMA statement for reporting systematic reviews and meta-analyses of studies that evaluate healthcare interventions: explanation and elaboration. *BMJ* 2009; 339: b2700.
21. Herzog R, Alvarez-Pasquin MJ, Diaz C, et al. Are healthcare workers' intentions to vaccinate related to their knowledge, beliefs and attitudes? A systematic review. *BMC Public Health* 2013; 13: 154.
22. Barendregt JJ, Doi SA, Lee YY, et al. Meta-analysis of prevalence. *J Epidemiol Community Health* 2013; 67: 974-978.
23. Duval S, Tweedie R. Trim and fill: a simple funnel-plot-based method of testing and adjusting for publication bias in meta-analysis. *Biometrics* 2000; 56: 455-463.
24. Dong Y, Mo X, Hu Y, et al. Epidemiology of COVID-19 Among Children in China. *Pediatrics* 2020; 145: e20200702.
25. Chen C, Cao M, Peng L, et al. Coronavirus Disease-19 Among Children Outside Wuhan, China. 2020. Available at: <https://ssrn.com/abstract=3546071> or <http://dx.doi.org/10.2139/ssrn.3546071>.
26. Wang D, Ju XL, Xie F, et al. Clinical analysis of 31 cases of 2019 novel coronavirus infection in children from six provinces (autonomous region) of northern China]. *Zhonghua Er Ke Za Zhi* 2020; 58: E011.
27. Tang A, Xu W, Chen P, et al. A retrospective study of the clinical characteristics of COVID-19 infection in 26 children. *medRxiv* 2020. DOI: <https://doi.org/10.1101/2020.03.08.20029710>.
28. Zheng F, Liao C, Fan QH, et al. Clinical characteristics of children with coronavirus disease 2019 in Hubei, China. *Curr Med Sci* 2020; 40: 275-280.
29. Xia W, Shao J, Guo Y, et al. Clinical and CT features in pediatric patients with COVID-19 infection: different points from adults. *Pediatr Pulmonol* 2020; 55: 1169-1174.
30. Feng K, Yun YX, Wang XF, et al. Analysis of CT features of 15 children with 2019 novel coronavirus infection. *Zhonghua Er Ke Za Zhi* 2020; 58: 275-278.
31. National Health Commission of the PRC. The Guidelines for the Diagnosis and Treatment of New Coronavirus Pneumonia. 2020. <http://www.nhc.gov.cn/yzygj/s7653p/202003/46c9294a7dfe4cef-80dc7f5912eb1989.shtml>.
32. Metlay JP, Waterer GW, Long AC, et al. Diagnosis and treatment of adults with community-acquired pneumonia. An official clinical practice guideline of the American Thoracic Society and Infectious Diseases Society of America. *Am J Respir Crit Care Med* 2019; 200: e45-e67.
33. Shi H, Han X, Jiang N, et al. Radiological findings from 81 patients with COVID-19 pneumonia in Wuhan, China: a descriptive study. *Lancet Infect Dis* 2020; 20: 425-434.
34. Guan WJ, Ni ZY, Hu Y, et al. Clinical characteristics of coronavirus disease 2019 in China. *N Engl J Med* 2020. DOI: 10.1056/NEJMoa2002032 [Online ahead of print].
35. Xu YH, Dong JH, An WM, et al. Clinical and computed tomographic imaging features of novel coronavirus pneumonia caused by SARS-CoV-2. *J Infect* 2020; 80: 394-400.
36. Chen G, Wu D, Guo W, et al. Clinical and immunologic features in severe and moderate forms of Coronavirus Disease 2019. *medRxiv* 2020. DOI: <https://doi.org/10.1101/2020.02.16.20023903>.
37. Zhang JJ, Dong X, Cao YY, et al. Clinical characteristics of 140 patients infected with SARS-CoV-2 in Wuhan, China. *Allergy* 2020; 75: 1730-1741.
38. Guan WJ, Ni ZY, Hu Y, et al.; China Medical Treatment Expert Group for COVID-19. Clinical characteristics of coronavirus disease 2019 in China. *N Engl J Med* 2020; 382: 1708-1720.
39. Cao W, Shi L, Chen L, et al. Clinical features and laboratory inspection of novel coronavirus pneumonia (COVID-19) in Xiangyang, Hubei. *medRxiv* 2020. DOI: <https://doi.org/10.1101/2020.02.23.20026963>.
40. Wan S, Xiang Y, Fang W, et al. Clinical features and treatment of COVID-19 patients in northeast Chongqing. *J Med Virol* 2020; 92: 797-806.
41. Zhang F, He L, Ouyang Y, et al. Clinical features of 81 hospitalized patients with 2019 novel coronavirus-infected pneumonia in Jingzhou, China: a descriptive study. 2020. Available at: <https://search.bvsalud.org/global-literature-on-novel-coronavirus-2019-ncov/resource/pt/ppcovidwho-559>.
42. Li K, Fang Y, Li W, et al. CT image visual quantitative evaluation and clinical classification of coronavirus disease (COVID-19). *Eur Radiol* 2020; 30: 4407-4416.
43. Liu KC, Xu P, Lv WF, et al. CT manifestations of coronavirus disease-2019: A retrospective analysis of 73 cases by disease severity. *Eur J Radiol* 2020; 126: 108941.
44. Qi D, Yan X, Tang X, et al. Epidemiological and clinical features of 2019-nCoV acute respiratory disease cases in Chongqing municipality, China: a retrospective, descriptive, multiple-center study. *medRxiv* 2020. DOI: <https://doi.org/10.1101/2020.03.01.20029397>.
45. Xu Z, Wu W, Jin Y, Pan A. Key points of clinical and CT imaging features of 2019 novel coronavirus (2019-nCoV) imported pneumonia based on 21 cases analysis. *medRxiv* 2020. DOI: <https://doi.org/10.1101/2020.03.03.20030775>.
46. Li K, Wu J, Wu F, et al. The clinical and chest CT features associated with severe and critical COVID-19 pneumonia. *Invest Radiol* 2020; 55: 327-331.
47. Liu L, Gao JY, Hu W, et al. Clinical characteristics of 51 patients discharged from hospital with COVID-19 in Chongqing, China. *medRxiv* 2020. DOI: <https://doi.org/10.1101/2020.02.20.20025536>.
48. Zhao W, Zhong Z, Xie X, et al. Relation between chest CT findings and clinical conditions of coronavirus disease (COVID-19) pneumonia: a multicenter study. *AJR Am J Roentgenol* 2020; 214: 1072-1077.
49. Zhou F, Yu T, Du R, et al. Clinical course and risk factors for mortality of adult inpatients with COVID-19 in Wuhan, China: a retrospective cohort study. *Lancet* 2020; 395: 1054-1062.
50. Li J, Long X, Luo H, et al. Clinical characteristics of deceased patients infected with SARS-CoV-2 in Wuhan, China. 2020. Available at: <https://ssrn.com/abstract=3546043> or <http://dx.doi.org/10.2139/ssrn.3546043>
51. Yuan M, Yin W, Tao Z, et al. Association of radiologic findings with mortality of patients infected with 2019 novel coronavirus in Wuhan, China. *PLoS One* 2020; 15: e0230548. DOI: 10.1371/journal.pone.0230548.

52. Wei Y, Lu Y, Xia L, et al. Analysis of 2019 novel coronavirus infection and clinical characteristics of outpatients: an epidemiological study from the fever clinic in Wuhan, China. *J Med Virol* 2020; 92: 2758-2767.
53. Liu H, Liu F, Li J, et al. Clinical and CT imaging features of the COVID-19 pneumonia: focus on pregnant women and children. *J Infect* 2020; 80: e7-e13. DOI: 10.1016/j.jinf.2020.03.007.
54. Li YY, Wang WN, Lei Y, et al. Comparison of the clinical characteristics between RNA positive and negative patients clinically diagnosed with coronavirus disease 2019. *Zhonghua Jie He He Hu Xi Za Zhi* 2020; 43: 427-430.
55. Zhu W, Xie K, Lu H, et al. Initial clinical features of suspected coronavirus disease 2019 in two emergency departments outside of Hubei, China. *J Med Virol* 2020; 92: 1525-1532.
56. Bai HX, Hsieh B, Xiong Z, et al. Performance of radiologists in differentiating COVID-19 from viral pneumonia on chest CT. *Radiology* 2020; 296: E46-E54. DOI: 10.1148/radiol.2020200823.
57. Liang Y, Liang J, Zhou Q, et al. Prevalence and clinical features of 2019 novel coronavirus disease (COVID-19) in the Fever Clinic of a teaching hospital in Beijing: a single-center, retrospective study. medRxiv 2020. DOI: <https://doi.org/10.1101/2020.02.25.20027763>.
58. Long C, Xu H, Shen Q, et al. Diagnosis of the coronavirus disease (COVID-19): rRT-PCR or CT? *Eur J Radiol* 2020; 126: 108961.
59. Cheng Z, Lu Y, Cao Q, et al. Clinical features and chest CT manifestations of coronavirus disease 2019 (COVID-19) in a single-center study in Shanghai, China. *AJR Am J Roentgenol* 2020; 215: 121-126.
60. Tang X, Du R, Wang R, et al. Comparison of hospitalized patients with acute respiratory distress syndrome caused by COVID-19 and H1N1. *Chest* 2020; 158: 195-205.
61. WHO. Coronavirus disease (COVID-2019): Similarities and differences between COVID-19 and influenza. 2020. Available at: <https://www.who.int/news-room/q-a-detail/q-a-similarities-and-differences-covid-19-and-influenza>.
62. Day M. Covid-19: four fifths of cases are asymptomatic, China figures indicate. *BMJ* 2020; 369: m1375. DOI: 10.1136/bmj.m1375.
63. van Doremalen N, Bushmaker T, Morris DH, et al. Aerosol and surface stability of SARS-CoV-2 as compared with SARS-CoV-1. *N Engl J Med* 2020; 382: 1564-1567.
64. WHO. Coronavirus disease (COVID-2019) situation report 79. 2020. Available at: <https://www.who.int/emergencies/diseases/novel-coronavirus-2019/situation-reports>.
65. Xu B, Kraemer MUG; Open COVID-19 Data Curation Group. Open access epidemiological data from the COVID-19 outbreak. *Lancet Infect Dis* 2020; 20: 534.
66. WHO. Global surveillance for COVID-19 caused by human infection with COVID-19 virus Interim guidance. 2020. Available at: <https://apps.who.int/iris/bitstream/handle/10665/331506/WHO-2019-nCoV-SurveillanceGuidance-2020.6-eng.pdf>.
67. Fang Y, Zhang H, Xie J, et al. Sensitivity of chest CT for COVID-19: comparison to RT-PCR. *Radiology* 2020; 296: E115-E117. DOI: 10.1148/radiol.2020200432.
68. Chen J, Wu L, Zhang J, et al. Deep learning-based model for detecting 2019 novel coronavirus pneumonia on high-resolution computed tomography. *Sci Rep* 2020; 10: 19196. DOI: 10.1038/s41598-020-76282-0.
69. Hope MD, Raptis CA, Shah A, et al. A role for CT in COVID-19? What data really tell us so far. *Lancet* 2020; 395: 1189-1190.
70. Nair A, Rodrigues JCL, Hare S, et al. A British Society of Thoracic Imaging statement: considerations in designing local imaging diagnostic algorithms for the COVID-19 pandemic. *Clin Radiol* 2020; 75: 329-334.
71. Kim EA, Lee KS, Primack SL, et al. Viral pneumonias in adults: radiologic and pathologic findings. *Radiographics* 2002; 22 (Suppl 1): S137-S149.
72. Koo HJ, Lim S, Choe J, et al. Radiographic and CT features of viral pneumonia. *Radiographics* 2018; 38: 719-739.
73. Kanne JP. Chest CT findings in 2019 novel coronavirus (2019-nCoV) infections from Wuhan, China: key points for the radiologist. *Radiology* 2020; 295: 16-17.
74. Chung M, Bernheim A, Mei X, et al. CT imaging features of 2019 novel coronavirus (2019-nCoV). *Radiology* 2020; 295: 202-207.
75. Song F, Shi N, Shan F, et al. Emerging 2019 novel coronavirus (2019-nCoV) pneumonia. *Radiology* 2020; 295: 210-217.
76. Xie X, Zhong Z, Zhao W, et al. Chest CT for typical 2019-nCoV pneumonia: relationship to negative RT-PCR testing. *Radiology* 2020; 296: E41-E45. DOI: 10.1148/radiol.2020200343.
77. Dong Y, Mo X, Hu Y, et al. Epidemiological characteristics of 2143 pediatric patients with 2019 coronavirus disease in China. *Pediatrics* 2020. DOI: [doi: 10.1542/peds.2020-0702](https://doi.org/10.1542/peds.2020-0702).
78. Shen KL, Yang YH (2020) Diagnosis and treatment of 2019 novel coronavirus infection in children: a pressing issue. *World J Pediatr* 2020; 16: 219-221.
79. Wu Z, McGoogan JM. Characteristics of and important lessons from the coronavirus disease 2019 (COVID-19) outbreak in China: summary of a report of 72 314 cases from the Chinese Center for Disease Control and Prevention. *JAMA* 2020; 323: 1239-1242.
80. Yang Y, Shen C, Li J, et al. Exuberant elevation of IP-10, MCP-3 and IL-1ra during SARS-CoV-2 infection is associated with disease severity and fatal outcome. medRxiv 2020. DOI: 10.1101/2020.03.02.20029975.
81. Tang X, Du R, Wang R, et al. Comparison of hospitalized patients with acute respiratory distress syndrome caused by COVID-19 and H1N1. *Chest* 2020; 158: 195-205.
82. Wang Y, Liu Y, Liu L, et al. Clinical outcomes in 55 patients with severe acute respiratory syndrome coronavirus 2 who were asymptomatic at hospital admission in Shenzhen, China. *J Infect Dis* 2020; 221: 1770-1774.
83. Hu Z, Song C, Xu C, et al. Clinical characteristics of 24 asymptomatic infections with COVID-19 screened among close contacts in Nanjing, China. *Sci China Life Sci* 2020; 63: 706-711.
84. Zhou X, Li Y, Li T, Zhang W. Follow-up of the asymptomatic patients with SARS-CoV-2 infection. *Clin Microbiol Infect* 2020; 26: 957-959.
85. Wang Y, Dong C, Hu Y, et al. Temporal changes of CT findings in 90 patients with COVID-19 pneumonia: a longitudinal study. *Radiology* 2020; 296: E55-E64. DOI: 10.1148/radiol.2020200843.
86. Hansell DM, Bankier AA, MacMahon H, et al. Fleischner Society: glossary of terms for thoracic imaging. *Radiology* 2008; 246: 697-722.
87. Chen T, Wu D, Chen H, et al. Clinical characteristics of 113 deceased patients with coronavirus disease 2019: retrospective study. *BMJ* 2020; 368: m1091. DOI: 10.1136/bmj.m1091.

88. Jabbari P, Jabbari F, Ebrahimi S, Rezaei N. COVID-19: a chimera of two pandemics. *Disaster Med Public Health Prep* 2020; 14: e38-e39. DOI: 10.1017/dmp.2020.223.
89. Hanaei S, Rezaei N. COVID-19: developing from an outbreak to a pandemic. *Arch Med Res* 2020; 51: 582-584.
90. Mohamed K, Rodríguez-Román E, Rahmani F, et al. International efforts to save healthcare personnel during COVID-19. *Acta Biomed* 2020; 91: e2020044. DOI: 10.23750/abm.v91i3.9891.
91. Lotfi M, Hamblin MR, Rezaei N. COVID-19: transmission, prevention, and potential therapeutic opportunities. *Clin Chim Acta* 2020; 508: 254-266.
92. Samieefar N, Yari Boroujeni R, Jamee M, et al. Country quarantine during COVID-19: critical or not? *Disaster Med Public Health Prep* 2021; 15: e24-e25. DOI: 10.1017/dmp.2020.384.
93. Basiri A, Heidari A, Nadi MF, et al. Microfluidic devices for detection of RNA viruses. *Rev Med Virol* 2021; 31: 1-11.
94. Sadeghmousavi S, Rezaei N. COVID-19 and multiple sclerosis: predisposition and precautions in treatment. *SN Compr Clin Med* 2020. DOI: 10.1007/s42399-020-00504-9.
95. Rabiee N, Rabiee M, Bagherzadeh M, Rezaei N. COVID-19 and picotechnology: potential opportunities. *Med Hypotheses* 2020; 144: 109917.
96. Mansourabadi AH, Sadeghalvad M, Mohammadi-Motlagh HR, Rezaei N. The immune system as a target for therapy of SARS-CoV-2: a systematic review of the current immunotherapies for COVID-19. *Life Sci* 2020; 258: 118185.
97. Mojtavabi H, Saghazadeh A, Rezaei N. Interleukin-6 and severe COVID-19: a systematic review and meta-analysis. *Eur Cytokine Netw* 2020; 31: 44-49.
98. Jahanshahlu L, Rezaei N. Monoclonal antibody as a potential anti-COVID-19. *Biomed Pharmacother* 2020; 129: 110337.
99. Basiri A, Pazhouhnia Z, Beheshtizadeh N, et al. Regenerative medicine in COVID-19 treatment: real opportunities and range of promises. *Stem Cell Rev Rep* 2021; 17: 163-175.
100. Seyedpour S, Khodaei B, Loghman AH, et al. Targeted therapy strategies against SARS-CoV-2 cell entry mechanisms: a systematic review of in vitro and in vivo studies. *J Cell Physiol* 2021; 236: 2364-2392.
101. Saghazadeh A, Rezaei N. Towards treatment planning of COVID-19: rationale and hypothesis for the use of multiple immunosuppressive agents: anti-antibodies, immunoglobulins, and corticosteroids. *Int Immunopharmacol* 2020; 84: 106560.
102. Fathi N, Rezaei N. Lymphopenia in COVID-19: therapeutic opportunities. *Cell Biol Int* 2020; 44: 1792-1797.
103. Shojaeefar E, Malih N, Rezaei N. The possible double-edged sword effects of vitamin D on COVID-19: a hypothesis. *Cell Biol Int* 2021; 45: 54-57.
104. Rezaei N. COVID-19 and medical biotechnology. *Avicenna J Med Biotechnol* 2020; 12: 139.
105. Sahu KK, Siddiqui AD, Rezaei N, Cerny J. Challenges for management of immune thrombocytopenia during COVID-19 pandemic. *J Med Virol* 2020; 92: 2277-2282.
106. Moazzami B, Razavi-Khorasani N, Dooghaie Moghadam A, et al. COVID-19 and telemedicine: Immediate action required for maintaining healthcare providers well-being. *J Clin Virol* 2020; 126: 104345.
107. Rezaei N. COVID-19 affects healthy pediatricians more than pediatric patients. *Infect Control Hosp Epidemiol* 2020; 41: 1106-1107.
108. Yazdanpanah N, Saghazadeh A, Rezaei N. Anosmia: a missing link in the neuroimmunology of coronavirus disease 2019 (COVID-19). *Rev Neurosci* 2020; 31: 691-701.
109. Yousefzadegan S, Rezaei N. Case report: Death due to COVID-19 in three brothers. *Am J Trop Med Hyg* 2020; 102: 1203-1204.
110. Rokni M, Hamblin MR, Rezaei N. Cytokines and COVID-19: friends or foes? *Hum Vaccin Immunother* 2020; 16: 2363-2365.
111. Ahanchian H, Moazzen N, Joghatayi SH, et al. Death due to COVID-19 in an infant with combined immunodeficiencies. *Endocr Metab Immune Disord Drug Targets* 2021; 21: 1649-1652.
112. Pourahmad R, Moazzami B, Rezaei N. Efficacy of plasmapheresis and immunoglobulin replacement therapy (IVIG) on patients with COVID-19. *SN Compr Clin Med* 2020. DOI: 10.1007/s42399-020-00438-2.
113. Darbeheshti F, Rezaei N. Genetic predisposition models to COVID-19 infection. *Med Hypotheses* 2020; 142: 109818.
114. Bahrami A, Vafapour M, Moazzami B, Rezaei N. Hyperinflammatory shock related to COVID-19 in a patient presenting with multisystem inflammatory syndrome in children: first case from Iran. *J Paediatr Child Health* 2021; 57: 922-925.
115. Yazdanpanah F, Hamblin MR, Rezaei N. The immune system and COVID-19: friend or foe? *Life Sci* 2020; 256: 117900.
116. Saghazadeh A, Rezaei N. Immune-epidemiological parameters of the novel coronavirus – a perspective. *Exp Rev Clin Immunol* 2020; 16: 465-470.
117. Pashaei M, Rezaei N. Immunotherapy for SARS-CoV-2: potential opportunities. *Exp Opin Biol Ther* 2020; 20: 1111-1116.
118. Sarzaeim M, Rezaei N. Kawasaki disease and multisystem inflammatory syndrome in children with COVID-19. *SN Compr Clin Med* 2020. DOI: 10.1007/s42399-020-00558-9.
119. Babaha F, Rezaei N. Primary immunodeficiency diseases in COVID-19 pandemic: a predisposing or protective factor? *Am J Med Sci* 2020; 360: 740-741.
120. Nasab MG, Saghazadeh A, Rezaei N. SARS-CoV-2 – a tough opponent for the immune system. *Arch Med Res* 2020; 51: 589-592.
121. Sharifkashani S, Bafrani MA, Khaboushan AS, et al. Angiotensin-converting enzyme 2 (ACE2) receptor and SARS-CoV-2: potential therapeutic targeting. *Eur J Pharmacol* 2020; 884: 173455.
122. Seyran M, Pizzol D, Adadi P, et al. Questions concerning the proximal origin of SARS-CoV-2. *J Med Virol* 2021; 93: 1204-1206.
123. Jahanshahlu L, Rezaei N. Central nervous system involvement in COVID-19. *Arch Med Res* 2020; 51: 721-722.
124. Ahanchian H, Moazzen N, Faroughi MSD, et al. COVID-19 in a child with primary specific antibody deficiency. *Res Square* 2020. DOI: <https://doi.org/10.21203/rs.3.rs-28155/v1>.
125. Goudarzi S, Dehghani Firouzabadi F, Dehghani Firouzabadi M, Rezaei N. Cutaneous lesions and COVID-19: cystic painful lesion in a case with positive SARS-CoV-2. *Dermatol Ther* 2020. DOI: 10.1111/dth.14266.
126. Saleki K, Banazadeh M, Saghazadeh A, Rezaei N. The involvement of the central nervous system in patients with COVID-19. *Rev Neurosci* 2020; 31: 453-456.
127. Heidarpour M, Vakhshoori M, Abbasi S, et al. Adrenal insufficiency in coronavirus disease 2019: a case report. *J Med Case Rep* 2020; 14: 134.

128. Lotfi M, Rezaei N. SARS-CoV-2: a comprehensive review from pathogenicity of the virus to clinical consequences. *J Med Virol* 2020; 92: 1864-1874.
129. Jabbari P, Rezaei N. With risk of reinfection, is COVID-19 here to stay? *Disaster Med Public Health Prep* 2020; 14: e33. DOI: 10.1017/dmp.2020.274.
130. Momtazmanesh S, Ochs HD, Uddin LQ, et al. All together to fight COVID-19. *Am J Trop Med Hygiene* 2020; 102: 1181-1183.
131. Mohamed K, Rodríguez-Román E, Rahmani F, et al. Borderless collaboration is needed for COVID-19 – a disease that knows no borders. *Infect Control Hosp Epidemiol* 2020; 41: 1245-1246.
132. Moradian N, Ochs HD, Sedikies C, et al. The urgent need for integrated science to fight COVID-19 pandemic and beyond. *J Transl Med* 2020; 18: 205.
133. Rzymiski P, Nowicki M, Mullin GE, et al. Quantity does not equal quality: scientific principles cannot be sacrificed. *Int Immunopharmacol* 2020; 86: 106711.
134. Mohamed K, Rezaei N. COVID-19 pandemic is not the time of trial and error. *Am J Emerg Med* 2021; 46: 774-775.
135. Zhu T, Wang Y, Zhou S, et al. A comparative study of chest computed tomography features in young and older adults with corona virus disease (COVID-19). *J Thorac Imaging* 2020; 35: W97-W101.
136. Liu W, Tao ZW, Lei W, et al. Analysis of factors associated with disease outcomes in hospitalized patients with 2019 novel coronavirus disease. *Chin Med J (Engl)* 2020; 133: 1032-1038.
137. Caruso D, Zerunian M, Polici M, et al. Chest CT features of COVID-19 in Rome, Italy. *Radiology* 2020; 296: E79-E85. DOI: 10.1148/radiol.2020201237.
138. Bernheim A, Mei X, Huang M, et al. Chest CT findings in coronavirus disease-19 (COVID-19): relationship to duration of infection. *Radiology* 2020; 295: 200463. DOI: 10.1148/radiol.2020200463.
139. Wu J, Wu X, Zeng W, et al. Chest CT findings in patients with corona virus disease 2019 and its relationship with clinical features. *Invest Radiol* 2020; 55: 257-261.
140. Liu Y, Yang Y, Zhang C, et al. Clinical and biochemical indexes from 2019-nCoV infected patients linked to viral loads and lung injury. *Sci China Life Sci* 2020; 63: 364-374.
141. Xiong Y, Sun D, Liu Y, et al. Clinical and high-resolution CT features of the COVID-19 infection: comparison of the initial and follow-up changes. *Invest Radiol* 2020; 55: 332-339.
142. Chen G, Wu D, Guo W, et al. Clinical and immunologic features in severe and moderate Coronavirus Disease 2019. *J Clin Invest* 2020; 130: 2620-2629.
143. Yang W, Cao Q, Qin L, et al. Clinical characteristics and imaging manifestations of the 2019 novel coronavirus disease (COVID-19): a multi-center study in Wenzhou city, Zhejiang, China. *J Infect* 2020; 80: 388-393.
144. Wang D, Hu B, Hu C, et al. Clinical characteristics of 138 hospitalized patients with 2019 novel coronavirus-infected pneumonia in Wuhan, China. *JAMA* 2020; 323: 1061-1069.
145. Liu M, He P, Liu HG, et al. Clinical characteristics of 30 medical workers infected with new coronavirus pneumonia. *Zhonghua Jie He He Hu Xi Za Zhi* 2020; 43: E016. DOI: 10.3760/cma.j.issn.1001-0939.2020.0016.
146. Zhang L, Zhu F, Xie L, et al. Clinical characteristics of COVID-19-infected cancer patients: a retrospective case study in three hospitals within Wuhan, China. *Ann Oncol* 2020; 31: 894-901.
147. Wu J, Liu J, Zhao X, et al. Clinical characteristics of imported cases of COVID-19 in Jiangsu province: a multicenter descriptive study. *Clin Infect Dis* 2020; 71: 706-712.
148. Liu K, Fang YY, Deng Y, et al. Clinical characteristics of novel coronavirus cases in tertiary hospitals in Hubei Province. *Chin Med J (Engl)* 2020; 133: 1025-1031.
149. Zhou F, Yu T, Du R, et al. Clinical course and risk factors for mortality of adult inpatients with COVID-19 in Wuhan, China: a retrospective cohort study. *Lancet* 2020; 395: 1054-1062.
150. Cao J, Tu WJ, Cheng W, et al. Clinical features and short-term outcomes of 102 patients with corona virus disease 2019 in Wuhan, China. *Clin Infect Dis* 2020; 71: 748-755.
151. Du Y, Tu L, Zhu P, et al. Clinical features of 85 fatal cases of COVID-19 from Wuhan: a retrospective observational study. *Am J Respir Crit Care Med* 2020; 201: 1372-1379.
152. Li Y, Xia L. Coronavirus disease 2019 (COVID-19): role of chest CT in diagnosis and management. *AJR Am J Roentgenol* 2020; 214: 1280-1286.
153. Zhou Z, Guo D, Li C, et al. Coronavirus disease 2019: initial chest CT findings. *Eur Radiol* 2020; 30: 4398-4406.
154. Zhou S, Wang Y, Zhu T, Xia L. CT features of coronavirus disease 2019 (COVID-19) pneumonia in 62 patients in Wuhan, China. *AJR Am J Roentgenol* 2020; 214: 1287-1294.
155. Han R, Huang L, Jiang H, et al. Early clinical and CT manifestations of coronavirus disease 2019 (COVID-19) pneumonia. *AJR Am J Roentgenol* 2020; 215: 338-343.
156. Song F, Shi N, Shan F, et al. Emerging 2019 novel coronavirus (2019-nCoV) pneumonia. *Radiology* 2020; 295: 210-217.
157. Qian GQ, Yang NB, Ding F, et al. Epidemiologic and clinical characteristics of 91 hospitalized patients with COVID-19 in Zhejiang, China: a retrospective, multi-centre case series. *QJM* 2020; 113: 474-481.
158. Zhang X, Cai H, Hu J, et al. Epidemiological, clinical characteristics of cases of SARS-CoV-2 infection with abnormal imaging findings. *Int J Infect Dis* 2020; 94: 81-87.
159. Chen Z, Fan H, Cai J, et al. High-resolution computed tomography manifestations of COVID-19 infections in patients of different ages. *Eur J Radiol* 2020; 126: 108972.
160. Zhang S, Li H, Huang S, et al. High-resolution CT features of 17 cases of corona virus disease 2019 in Sichuan province, China. *Eur Respir J* 2020; 55: 2000334.
161. Xu X, Yu C, Qu J, et al. Imaging and clinical features of patients with 2019 novel coronavirus SARS-CoV-2. *Eur J Nucl Med Mol Imaging* 2020; 47: 1275-1280.
162. Guan CS, Lv ZB, Yan S, et al. Imaging features of coronavirus disease 2019 (COVID-19): evaluation on thin-section CT. *Acad Radiol* 2020; 27: 609-613.
163. Wang K, Kang S, Tian R, et al. Imaging manifestations and diagnostic value of chest CT of coronavirus disease 2019 (COVID-19) in the Xiaogan area. *Clin Radiol* 2020; 75: 341-347.
164. Pan Y, Guan H, Zhou S, et al. Initial CT findings and temporal changes in patients with the novel coronavirus pneumonia (2019-nCoV): a study of 63 patients in Wuhan, China. *Eur Radiol* 2020; 30: 3306-3309.

165. Wu J, Feng CL, Xian XY, et al. Novel coronavirus pneumonia (COVID-19) CT distribution and sign features. *Zhonghua Jie He He Hu Xi Za Zhi* 2020; 43: E030. DOI: 10.3760/cma.j.cn112147-20200217-00106.
166. Han X, Cao Y, Jiang N, et al. Novel coronavirus pneumonia (COVID-19) progression course in 17 discharged patients: comparison of clinical and thin-section CT features during recovery. *Clin Infect Dis* 2020; 71: 723-731.
167. Shi H, Han X, Jiang N, et al. Radiological findings from 81 patients with COVID-19 pneumonia in Wuhan, China: a descriptive study. *Lancet Infect Dis* 2020; 20: 425-434.
168. Zhou Y, Zhang Z, Tian J, Xiong S. Risk factors associated with disease progression in a cohort of patients infected with the 2019 novel coronavirus. *Ann Palliat Med* 2020; 9: 428-436.
169. Zhao X, Liu B, Yu Y, et al. The characteristics and clinical value of chest CT images of novel coronavirus pneumonia. *Clin Radiol* 2020; 75: 335-340.
170. Pan F, Ye T, Sun P, et al. Time course of lung changes on chest CT during recovery from 2019 novel coronavirus (COVID-19) pneumonia. *Radiology* 2020; 295: 715-721.
171. Fu H, Li H, Tang X, et al. Analysis on the clinical characteristics of 36 cases of novel coronavirus pneumonia in Kunming. medRxiv 2020. DOI: doi: <https://doi.org/10.1101/2020.02.28.20029173>.
172. Liu R, Ming X, Zhu H, et al. Association of cardiovascular manifestations with in-hospital outcomes in patients with COVID-19: a hospital staff data. medRxiv 2020. DOI: <https://doi.org/10.1101/2020.02.29.20029348>.
173. Huang Y, Zhou H, Yang R, et al. Clinical characteristics of 36 non-survivors with COVID-19 in Wuhan, China. medRxiv 2020. DOI: <https://doi.org/10.1101/2020.02.27.20029009>.
174. Cao M, Zhang D, Wang Y, et al. Clinical features of patients infected with the 2019 novel coronavirus (COVID-19) in Shanghai, China. medRxiv 2020. DOI: <https://doi.org/10.1101/2020.03.04.20030395>
175. Zhao W, Zhong Z, Yu Q, et al. Clinical outcomes of patients with 2019-nCoV: a preliminary summary. 2020. Available at: <https://ssrn.com/abstract=3542167> or <http://dx.doi.org/10.2139/ssrn.3542167>.
176. Lei ZY, Cao HJ, Jie YS, et al. Comparison of epidemiological and clinical features of patients with coronavirus disease (COVID-19) in Wuhan and outside Wuhan, China. *Travel Med Infect Dis* 2020; 35: 101664.
177. Lu C, Yang W, Hu Y, et al. Coronavirus disease 2019 (COVID-19) pneumonia: early stage chest CT imaging features and clinical relevance. Available at: <https://ssrn.com/abstract=3543606> or <http://dx.doi.org/10.2139/ssrn.3543606>.
178. Feng Z, Yu Q, Yao S, et al. Early prediction of disease progression in 2019 novel coronavirus pneumonia patients outside Wuhan with CT and clinical characteristics. medRxiv 2020. DOI: <https://doi.org/10.1101/2020.02.19.20025296>.
179. Li J, Li S, Cai Y, et al. Epidemiological and clinical characteristics of 17 hospitalized patients with 2019 novel coronavirus infections outside Wuhan, China. medRxiv 2020. DOI: <https://doi.org/10.1101/2020.02.11.20022053>.
180. Chen X, Zheng F, Qing Y, et al. Epidemiological and clinical features of 291 cases with coronavirus disease 2019 in areas adjacent to Hubei, China: a double-center observational study. medRxiv 2020. DOI: <https://doi.org/10.1101/2020.03.03.20030353>.
181. Zhu Z, Tang J, Chai X, et al. How to differentiate COVID-19 pneumonia from heart failure with computed tomography at initial medical contact during epidemic period. medRxiv 2020. DOI: <https://doi.org/10.1101/2020.03.04.20031047>.
182. Ng MY, Lee EY, Yang J, et al. Imaging profile of the COVID-19 infection: radiologic findings and literature review. *Radiol Cardiothorac Imaging* 2020; 2: e200034. DOI: 10.1148/ryct.2020200034.
183. Qiu C, Xiao Q, Liao X, et al. Transmission and clinical characteristics of coronavirus disease 2019 in 104 outside-Wuhan patients, China. medRxiv 2020. DOI: <https://doi.org/10.1101/2020.03.04.20026005>.
184. Zhao D, Yao F, Wang L, et al. A comparative study on the clinical features of COVID-19 pneumonia to other pneumonias. *Clin Infect Dis* 2020; 71: 756-761.
185. Rezaei N. Coronavirus Disease-COVID-19. Springer International Publishing AG; 2021.