



Received: 2016.04.28
Accepted: 2016.05.10
Published: 2017.01.12

Authors' Contribution:

- A** Study Design
- B** Data Collection
- C** Statistical Analysis
- D** Data Interpretation
- E** Manuscript Preparation
- F** Literature Search
- G** Funds Collection

Critical Hand Ischemia After Radial Access for Coronary Angiography – Case Report

Krzysztof Bojakowski¹**ABCDEF**, Michał Zawadzki²**ABCDEF**, Bartosz Mruk²**ADEF**,
Piotr Andziak¹**ADEF**, Jerzy Walecki^{2,3}**ADEF**

¹ Department of General and Vascular Surgery, Central Clinical Hospital of the Ministry of Internal Affairs, Warsaw, Poland

² Department of Diagnostic and Interventional Radiology, Central Clinical Hospital of the Ministry of Internal Affairs, Warsaw, Poland

³ Department of Diagnostic and Interventional Radiology, Medical Centre for Postgraduate Education, Warsaw, Poland

Author's address: Bartosz Mruk, Department of Diagnostic and Interventional Radiology, Central Clinical Hospital of the Ministry of Internal Affairs, Wołoska 137 Str., 02-507 Warsaw, Poland, e-mail: bartosz.mruk@hotmail.com

Summary

Background:

Radial artery is now the most frequent access for coronary angiography and intervention. Despite the common opinion that it is safer than femoral access, it has the potential for serious complications. One of them is upper limb ischemia caused by radial artery thrombosis.

Case Report:

We are presenting a case of critical hand ischemia after coronary angiography performed through radial access despite existing risk factors, which may be considered as relative contraindications.

Conclusions:

In the presented case, decision was made to use radial access despite several risk factors of upper limb ischemia – diabetes, end-stage renal failure, hyperparathyroidism, or even symptoms of left upper limb ischemia. Furthermore, for diagnostic coronary angiography 5F instead of 4F introducer was used.

MeSH Keywords:

Coronary Angiography • Embolism and Thrombosis • Ischemia

PDF file:

<http://www.polradiol.com/abstract/index/idArt/899334>

Background

Radial artery is now considered as the main access for coronary angiography and angioplasty. It has been proved that it possess lower risk of local complications including hemorrhage and pseudoaneurysm formation as compared to femoral access [1]. Lower mortality rate and shorter hospitalization time have also been reported in groups of patients treated via radial access. In many centers it is the first-line access for any percutaneous coronary intervention [2].

Despite all the mentioned benefits of radial access it also possess drawbacks. After puncture and guiding sheath introduction, radial artery thrombosis occurs in 2–18% of cases [3,4]. Brachial artery occlusion after radial artery access has also been reported [5].

In many of these patients it is asymptomatic or symptoms are transient [6,7]. However, sometimes it may lead to

acute hand ischemia or even hand amputation [4]. In these cases it is considered that emboli to hand arches and digital arteries may separate from a thrombus in the radial artery, or ischemia can be caused by the thrombosis of small distal arteries [4].

Case Report

A 63-year-old male was admitted to our Clinic with critical both upper limbs ischemia presenting with rest pain and ulcerations of both hands. Pain was stronger in the right hand. The largest ulceration measuring 10 over 20 mm was located on the palmar surface of the left thumb (Figure 1A). Small punctate ulcerations with a maximum diameter of 3 mm were also noted on other fingers (Figure 1B). Distal phalanx necrosis of the right thumb had 15 mm (Figure 1B).

Symptoms occurred right after the coronary angiography performed through radial access (5F sheath) of the right hand and were gradually increasing over five weeks.

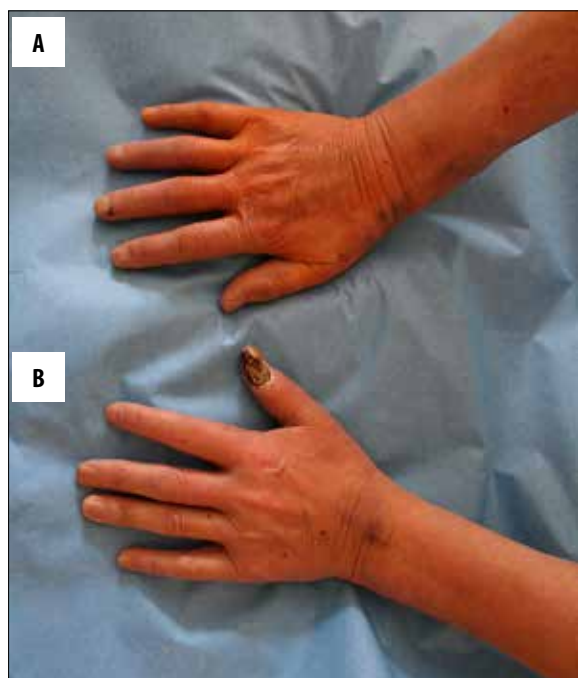


Figure 1. Ulceration on the palmar surface of the left thumb (A), small punctate ulcerations on other fingers and distal phalanx necrosis of the right thumb (B).

Comorbidities included: coronary heart disease (CCS III), myocardial infarction in 1990, chronic heart failure (NYHA IV), end-stage renal disease (dialyzed for 15 months), secondary parathyroidism, insulin-dependent type II diabetes, atrial fibrillation, hypothyroidism and chronic lower limb ischemia.

Right leg (below the knee) and left forefoot amputation were performed in 2004 due to irreversible ischemia and necrosis. Due to chronic renal insufficiency brachio-cephalic dialysis fistula was created on the left arm in 2006, which due to hand ischemia was reconstructed in 2007 using DRIL method (distal revascularization-interval ligation) technique. His medications included statins, dual antiplatelet therapy, insulin, low molecular weight heparin and thyroid hormone replacement therapy.

On clinical examination temperature of both hands was lowered and ulcerations were present. Pulse in the right upper extremity was palpable only on the right brachial artery. There was pulse deficit on the left radial artery with palpable pulse wave on the brachial artery.

Doppler ultrasound examination of the right arm revealed no flow in the radial artery and only faint flow in the proximal part of the ulnar artery. On Doppler ultrasound performed in the left arm, steal syndrome from the shunt was observed with a faint flow within the distal brachial and radial arteries (below the arterial anastomosis of the shunt).

On arteriography of the right upper extremity performed from right femoral access we noticed a hemodynamically-insignificant calcified ostial stenosis of the right subclavian artery (Figure 2A). Axillary, brachial and

intercostal arteries were patent without significant stenosis (Figure 2A, 2B). Radial artery was occluded; ulnar artery was patent in the proximal part, the middle part was occluded and the distal part filled up from collaterals (Figure 2C). Ulnar artery remained the main supply for the hand arches (Figure 2D). On the left side the subclavian, axillary and brachial arteries were patent and a steal syndrome to the dialysis fistula was observed. Ulnar and radial arteries were patent with slow flows. Moreover, a significant stenosis of the brachio-brachial by-pass distal to the arterio-venous fistula were noticed.

Based on clinical symptoms and arteriography, the patient was qualified to surgical thrombectomy of the right radial artery. It was performed through a distal part of the artery, just above the wrist. Intraoperatively, advanced hemodynamically significant atherosclerotic changes were observed with thrombus occluding the lumen of the artery. Thrombus was removed and a good inflow was obtained. After surgery, the clinical status of the limb improved, and pain subsided.

Unfortunately, after 14 hours ischemia relapsed, and again, thrombosis of the radial artery was observed in ultrasound. This time endovascular treatment was performed through the right femoral access. On angiography, radial artery was completely occluded, ulnar artery was patent in its proximal and distal part with a 10-cm calcified occlusion in the middle part (Figure 3A). Occlusion was crossed with a V18 wire and dilated using a 2/120mm Biotronic Passeo 18 angioplasty balloon (12 atm) (Figure 3B, 3C). After angioplasty, good inflow to hand arterial arches was observed (Figure 3D). There was improvement in hand perfusion after treatment with a significant reduction in pain.

Discussion

To decrease the risk of hand ischemia before making the decision on radial artery access, the Allen test is performed. It assesses sufficiency of the ulnar artery supply to the hand and if it is safe to puncture the radial artery. It is positive in 6,4 to 27% of all patients in whom coronary angiography was performed [7]. Many authors stress that clinical examination has limited specificity, which can be caused by delayed filling through collaterals between forearm arteries [8]. The use of Doppler ultrasound examination and pulseoxymetry is helpful in showing sufficient ulnar supply to the hand in patients with positive Allen test results [8]. However, in those patients, despite the lack of symptoms of hand ischemia, an increased level of lactic acid in capillary blood taken from the thumb is observed. It is postulated by some authors to avoid radial access in all patients with a positive Allen test, excluding those in whom femoral access is very risky or impossible.

Following risk factors for radial artery thrombosis have been described: small diameter of radial artery, small ratio of radial artery diameter and introducer sheath diameter, introducer sheath diameter itself, hypotension during the procedure, many arterial puncture attempts, high doses of vasoconstrictors and non-use of statins in patients undergoing coronary angiography [9,10].

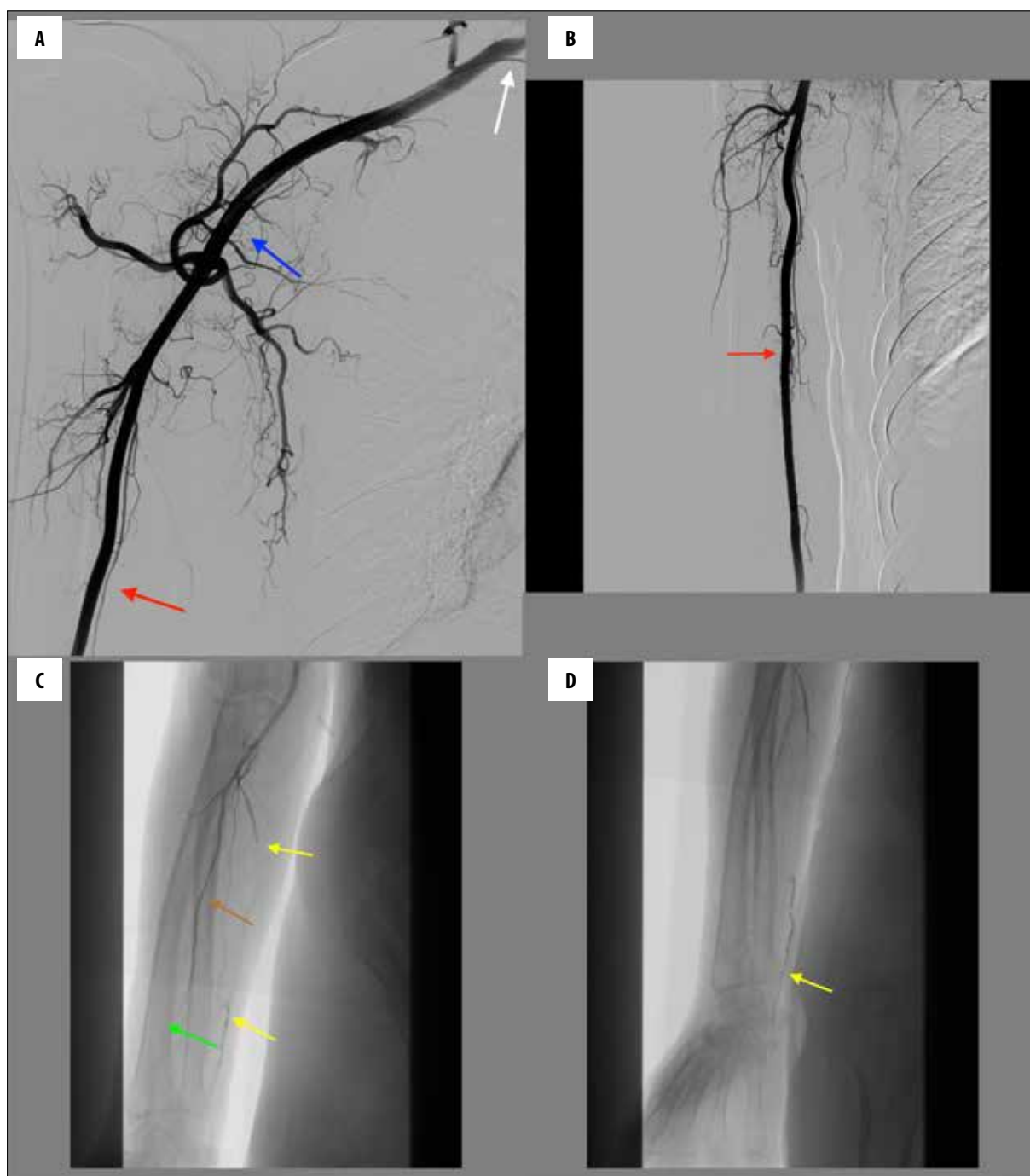


Figure 2. (A–D) Right upper extremity arteriography. Hemodynamically insignificant ostial stenosis of the right subclavian artery (white arrow). Axillary (blue arrow), brachial (red arrow) and intercostal (brown arrow) arteries are patent without significant stenosis. Radial artery occlusion (green arrow); ulnar artery (yellow arrow) is patent in the proximal part, the middle part is occluded and the distal part fills up from collaterals. Ulnar artery (yellow arrow) remains the main supply for the hand arches.

Risk of radial artery occlusion significantly increases with introducer sheath diameter, being significantly higher with sheaths >4F (2.67% with 4F sheaths as compared to 11.8% with 5F sheaths).

High cardiovascular risk patients with diabetes, renal failure, on dialysis have also a higher risk of upper limb ischemia [6]. In this group of patients peripheral neuropathy, muscles dysfunctions and other hand dysfunctions are

more common, and the assessment of the grade of ischemia is difficult. In patients with renal failure, atherosclerotic stenosis of the radial artery is more common, and, in consequence, the complication rate significantly increases [6].

In patients with renal failure, radial artery is used for the creation of the most preferred dialysis access – radio-cephalic fistula in the forearm. In case of radial artery occlusion it is impossible to create such a fistula.

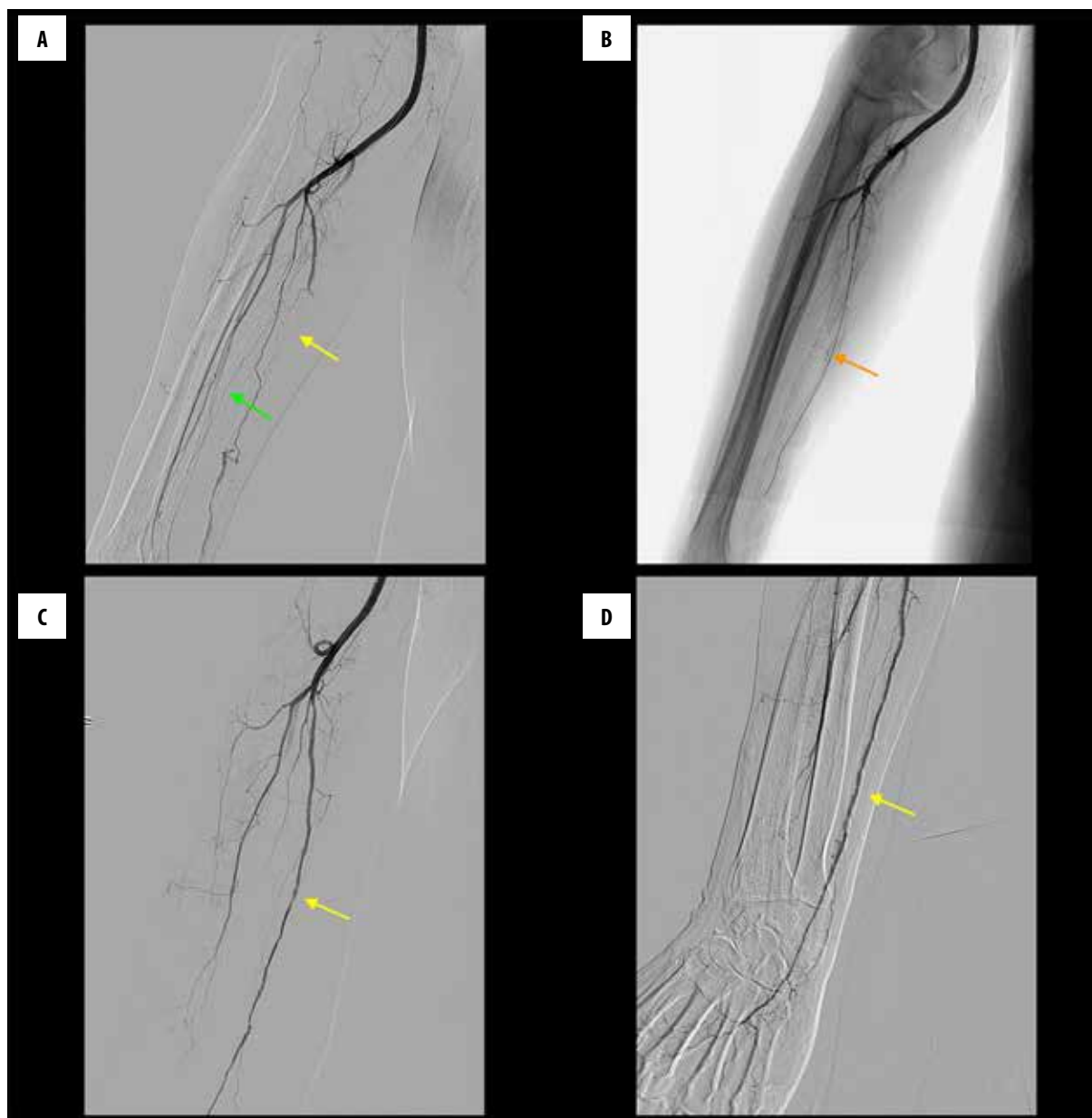


Figure 3. Endovascular recanalization of ulnar artery occlusion. Arteriography before treatment – ulnar artery (yellow arrow) and radial artery (green arrow) occlusion (A). The guidewire (V18) was advanced to the ulnar artery (orange arrow – B). The final angiographic result shows recanalization of the ulnar artery (yellow arrow – C, D).

Interventional cardiologist must take it into account before making his/her decision on radial access for coronary angiography or intervention.

In the presented case decision was made to use radial access despite several risk factors of upper limb ischemia – diabetes, end-stage renal failure, hyperparathyroidism, or even symptoms of left upper limb ischemia. Furthermore, for diagnostic coronary angiography, 5F instead of 4F introducer was used.

Treatment of upper limb ischemia caused by iatrogenic occlusion of the radial artery is complicated and may end up with limb amputation [3]. Surgical recanalization with occlusion of the incision site with a vascular patch has a

very high complication rate – re-occlusion after 24 h is observed in $\frac{3}{4}$ of patients [3]. It is considered that critical hand ischemia after instrumentation on the radial artery may be caused by small emboli to digital arteries, which may explain the low efficacy of reconstructive surgery [3].

Outflow problems are also the main cause of failure of endovascular treatment of critical upper limb ischemia [6].

In selected cases with a high risk of amputation, when surgery and endovascular approaches fail, non-standard methods like surgical venous arterialization are sometimes used.

Conclusions

The presented case of critical upper limb ischemia caused by radial artery puncture for coronary angiography indicates the high risk of this arterial access in renal failure patients.

We managed to recanalize the ulnar artery with resulting sufficient blood supply to the hand, but the radial artery despite surgical attempts remained occluded. It has to be stressed that due to limited possibilities of endovascular

and surgical treatment, complications of radial access in renal failure patients may lead up even to upper limb amputation.

Therefore, in this group of patients, the Allen test and ultrasound examination of the forearm arteries must be performed, and in case of any doubts, another access site should be considered if possible. Our clinical observations also indicate that 4F instead of 5F introducer sheaths should be used for radial access whenever possible.

References:

1. Nathan S, Rao SV: Radial versus femoral access for percutaneous coronary intervention: Implications for vascular complications and bleeding. *Curr Cardiol Rep*, 2012; 14: 502–9
2. Joyal D, Bertrand OF, Rinfret S et al: Meta-analysis of ten trials on the effectiveness of the radial versus the femoral approach in primary percutaneous coronary intervention. *Am J Cardiol*, 2012; 109: 813–18
3. Valentine RJ, Modrall JG, Clagett GP: Hand ischemia after radial artery cannulation. *J Am Coll Surg*, 2005; 201: 18–22
4. Rademakers LM, Laarman GJ: Critical hand ischaemia after transradial cardiac catheterisation: an uncommon complication of a common procedure. *Neth Heart J*, 2012; 20: 372–75
5. Sang Y, Jin H, Liu Y: Case report A case of acute brachial artery occlusion after transradial coronary intervention. *Postep Kardiol Inter*, 2013; 9(2): 184–86
6. Ferraresi R, Pallosi A, Aprigliano G et al: Angioplasty of below-the-elbow arteries in critical hand ischaemia. *Eur J Vasc Endovasc Surg*, 2012; 43: 73–80
7. Kanei Y, Kwan T, Nakra NC et al: Transradial cardiac catheterization: A review of access site complications. *Catheter Cardiovasc Interv*, 2011; 78: 840–46
8. Barbeau GR, Arsenault F, Dugas I et al: Evaluation of the ulnopalmar arterial arches with pulse oximetry and plethysmography: comparison with the Allen's test in 1010 patients. *Am Heart J*, 2004; 147: 489–93
9. Brzezinski M, Luisetti T, London MJ: Radial artery cannulation: A comprehensive review of recent anatomic and physiologic investigations. *Anesth Analg*, 2009; 109: 1763–81
10. Honda T, Fujimoto K, Miyao Y et al: Access site-related complications after transradial catheterization can be reduced with smaller sheath size and statins. *Cardiovasc Interv Ther*, 2012; 27: 174–80