



Received: 2016.06.04
Accepted: 2016.09.01
Published: 2017.04.16

Authors' Contribution:

- A** Study Design
- B** Data Collection
- C** Statistical Analysis
- D** Data Interpretation
- E** Manuscript Preparation
- F** Literature Search
- G** Funds Collection

Herlyn-Werner-Wunderlich Syndrome: Sonographic and Magnetic Resonance (MR) Imaging Findings of This Rare Urogenital Anomaly

Sukriye Yilmaz^{1BEF}, Adalet Elcin Yildiz^{1ABCE}, Suat Fitoz^{2E}

¹ Department of Radiology, Ankara Child Health, Haematology, Oncology Education and Research Hospital, Ankara, Turkey

² Department of Paediatric Radiology, Faculty of Medicine, Ankara University, Ankara, Turkey

Author's address: Adalet Elcin Yildiz, Department of Radiology, Ankara Child Health, Haematology, Oncology Education and Research Hospital, Ankara, Turkey, e-mail: aelcindr@gmail.com

Background:

Herlyn-Werner-Wunderlich syndrome is a rare congenital urogenital anomaly characterised by uterus didelphys with blind hemivagina and ipsilateral renal agenesis. Children usually have progressive pelvic pain after menarche, palpable mass due to hemihaemato(metro)colpos or pelvic inflammatory disease. The diagnosis usually requires a suspicion of this rare genitourinary syndrome.

Case Reports:

We present ultrasonography and MR imaging findings of this rare anomaly in two cases.

Conclusions:

Early recognition of this rare syndrome can lead to an immediate, proper surgical intervention and is necessary to prevent complications and preserve future fertility. Ultrasound and MR imaging findings can collectively delineate uterine morphology, indicate the absence of ipsilateral kidney and show obstructed hemivagina.

MeSH Keywords:

Magnetic Resonance Imaging • Ultrasonography, Doppler, Color • Urogenital Abnormalities

PDF file:

<http://www.polradiol.com/abstract/index/idArt/899889>

Summary

Background

The internal genitals and lower urinary tract originate from two embryonic urogenital structures called the Wolffian (mesonephric) ducts and the Müllerian (paramesonephric) ducts. Müllerian ducts, which are located lateral to the Wolffian ducts, grow downwards and towards the midline and form the uterovaginal canal. The uterovaginal canal differentiates into the fallopian tubes, uterus and upper two thirds of vagina. The lower third of the vagina derives from the urogenital sinus [1,2]. Due to different embryological origins of the lower third of the vagina and the rest of the Müllerian organs, their anomalies can be isolated or combined. Moreover, the embryonal development of the urinary system is in a close relationship with the reproductive system, which explains the combination of urinary and reproductive tract anomalies.

Herlyn-Werner-Wunderlich (HWW) syndrome, characterised by uterus didelphys with blind hemivagina and ipsilateral renal agenesis, is a rare Müllerian duct anomaly [3].

Diagnosis is generally delayed because of regular menses from the non-obstructed hemivagina. Progressive pelvic pain after menarche, pelvic mass and pelvic inflammatory disease are the most pronounced symptoms. Ultrasonography is generally the initial imaging modality and being familiar with characteristics of this rare syndrome makes the diagnosis easier. MR imaging provides more detailed anatomic information and supports the diagnosis [4–6]. In order to avoid complications of this rare anomaly, early and accurate diagnosis is important. We aim to present sonographic and MR imaging findings of this rare anomaly in two cases.

Case Report

Case 1

A 13 year-old girl presented to the emergency department with increasing pelvic pain and bad-smelling, green-coloured vaginal discharge (pelvic inflammatory disease). Her first menarche occurred 3 months before, her cycles

were regular but with severe dysmenorrhoea. She was admitted to our hospital one month earlier with similar complaints. She was referred to the radiology department for pelvic ultrasonography, which revealed uterus didelphys, haematocolpos and agenesis of the left kidney. Both uteri were normal in size and shape. There was no fluid in the endometrial cavities. The left hemivagina was distended with fluid content, and there was also fluid in the right hemivagina with similar properties (Figure 1A). Pelvic MR imaging was performed to study the abnormalities in detail. MR imaging confirmed two separate uteri with two separate cervixes (uterus didelphys bicollis) and two proximal vaginas (Figure 1B). Both hemivaginas were distended and filled with hyperintense fluid on T1-weighted images and a slightly hypointense fluid on T2-weighted images, suggesting a blood collection (haematocolpos). There was also a tubular structure inside the lateral wall of the left hemivagina that could be an urethral remnant (Figure 1C). Her surgical follow-up is not known.

Case 2

A 15-year-old girl was admitted to the emergency department with dysmenorrhoea. She had experienced menarche when she was 13 years old and had a history of regular menses with cyclic pelvic pain. Moreover, she had a solitary kidney. Her past medical and surgical history was otherwise unremarkable. Physical examination and laboratory findings were normal. She was referred to the radiology department for pelvic ultrasonography, which showed uterus didelphis and left-sided dilated hemivagina with echogenic content (Figure 2A). The right kidney was absent and the left kidney was hypertrophic (Figure 2B, 2C). In order to delineate the anatomic structures in detail and evaluate the content of the hemivagina, we performed pelvic MR imaging. Uterus didelphis was confirmed, and a distended left hemivagina with T1- and T2-hyperintense fluid consistent with haemorrhage was depicted (Figure 2D, 2E). The right hemivagina was normal in shape. After surgical removal of the left hemivaginal septum her pain was relieved.

Discussion

Mullerian (paramesonephric) duct anomalies are congenital anomalies of the female genital tract resulting from nondevelopment or non-fusion of the Mullerian ducts or an incomplete resorption of the uterine septum during the sixth to ninth week of foetal life, which causes a wide range of reproductive duct malformations [4,5]. The paramesonephric ducts of the genetically female embryo fuse together in the midline and form the uterus, cervix and the upper two thirds of vagina. The lower third of vagina is formed from sinovaginal bulbs which are protrusions of the urogenital sinus [6].

The urinary and genital systems arise from a common ridge of mesoderm along the dorsal body wall. Therefore, abnormal differentiation of the mesonephric and paramesonephric ducts may also be associated with anomalies of the kidneys [6]. Agenesis of one kidney is the most common anomaly but horseshoe or pelvic kidney, cystic renal dysplasia, duplication of the collecting system and ectopic

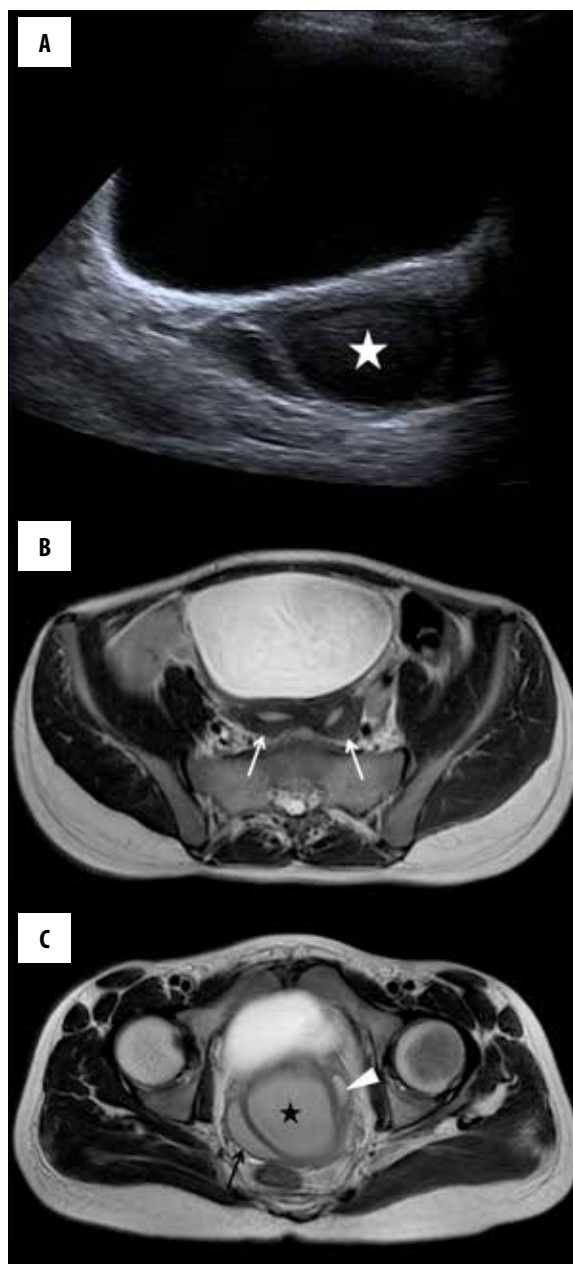
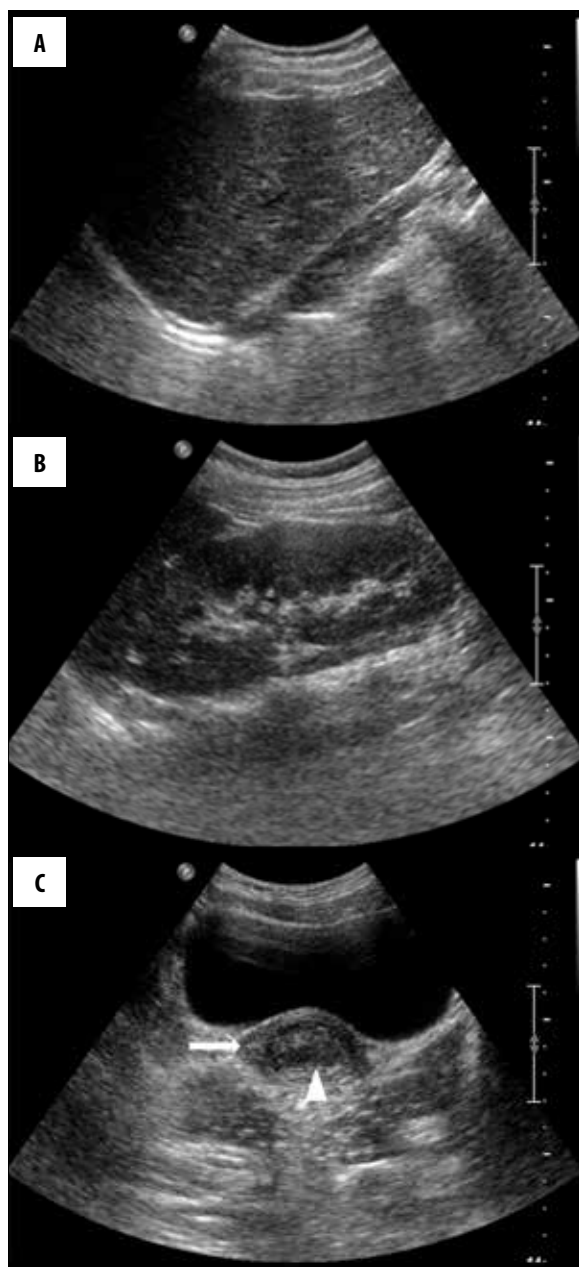


Figure 1. A 13-year-old girl with pelvic pain and bad-smelling, green-coloured vaginal discharge, case 1. On axial sonography at the level of the vaginas, (A) more to the left side (star), both hemivaginas are dilated and have fluid echoes. Axial T2W images at the level of uterus (B) and vaginas (C) show uterus didelphis and dilated right (arrow) and left (star) hemivaginas with slightly hypointense fluid contents consistent with haematocolpos. Note the tubular cystic structure in the wall of the left hemivagina (arrowhead).

ureters can also be seen [6,7]. Renal agenesis is associated with an ipsilateral obstructive Mullerian anomaly in more than 50% of cases [7]. These anomalies have a right-sided dominance [8,9]. Such a relationship between female genital and urogenital anomalies should lead clinicians to investigate the urogenital system when a genital anomaly is identified [10].



Herlyn-Werner-Wunderlich (HWW) syndrome is generally diagnosed at puberty with symptoms of progressive and recurrent pelvic pain, dysmenorrhea, a palpable mass due to hemato(metro)colpos following menarche, as was seen in our cases. A presentation with an abnormal vaginal discharge due to pelvic inflammatory disease has also been reported, and was also seen in our patient (case 1). If treatment is delayed, complications may develop. Therefore, early detection of this rare anomaly is important to avoid complications and preserve fertility. Endometriosis may occur due to retrograde menstruation. Infection and pelvic adhesions may develop due to the obstruction created by the vaginal septum. The diagnosis of this anomaly is generally delayed because of regular menstruation from the normally bleeding hemivagina [11].

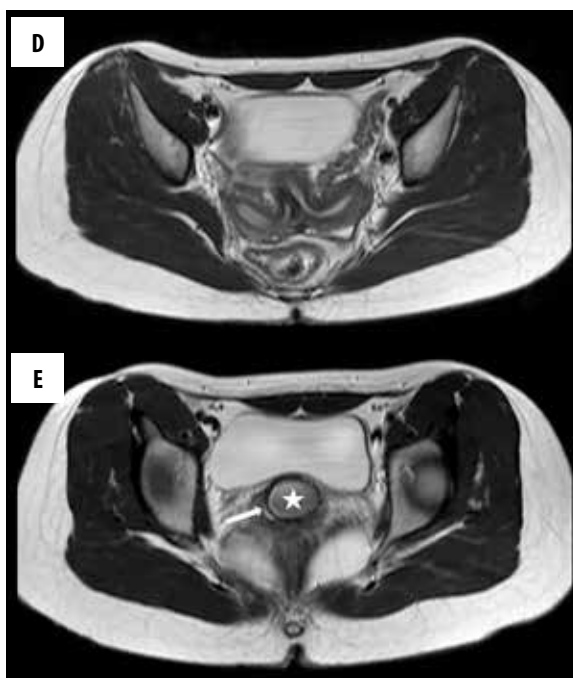


Figure 2. A 15-year-old girl with dysmenorrhea, case II. On a sagittal view, the right kidney (A) was absent and the left kidney (B) was hypertrophic. Axial sonography image (C) demonstrates dilated left hemivagina with echogenic content (arrowhead) and normal right hemivagina (arrow). Axial T2W images at the level of uterus (D) and vaginas (E) show uterus didelphys and dilated left hemivagina with slightly hypointense fluid consistent with haematocolpos (star) and normal right hemivagina (arrow).

Ultrasonography is the modality of choice due to its wide availability. If one suspects uterine abnormalities, kidneys should be examined during the same ultrasound session. MRI is the gold standard modality for making the diagnosis and planning surgical treatment. MRI is superior due to its multiplanar capability, high soft tissue contrast and a better characterization of pelvic anatomy. MR imaging enables more detailed depiction of the uterus didelphys by demonstrating two separate uteri, each with a normal zonal anatomy, myometrium, endometrium and two separate cervixes along with two hemivaginas. The vaginal septum can be located at the level of obstruction. The unilateral hemivaginal septum leads to haematometra and haematocolpos. Haematometra is diagnosed as markedly distended endometrial cavity with characteristic high signal intensity on T1-weighted images, indicating blood products [5,6,11].

Our patients were typical cases of uterus didelphys, transverse septum in the midhemivagina and ipsilateral renal agenesis.

Conclusions

The diagnosis of Herlyn-Werner-Wunderlich (HWW) syndrome requires suspicion of this rare genitourinary syndrome. Early recognition of this rare syndrome can lead to immediate, proper surgical intervention and is necessary to prevent complications and preserve future fertility. Ultrasound and MR imaging findings can collectively

delineate uterine morphology, show the absence of ipsilateral kidney and obstructed hemivaginas. The cooperation between paediatricians, paediatric surgeons, radiologists and gynaecologists is essential to avoid complications due to diagnostic delay.

Statement

No funding was received from any source. The authors declare no conflicts of interest.

References:

1. Sadler TW, Langman J (eds.): Langman's medical embryology, 8th edn. Lippincott Williams & Wilkins, Philadelphia, 2000
2. Kiechl-Kohlendorfer U, Geley TE, Unsinn KM et al: Diagnosing neonatal female genital anomalies using saline enhanced sonography. *Am J Roentgenol*, 2001; 177: 1041–44
3. Purslow CE: A case of unilateral haematocolpos, haematometra and haematosalpinx. *J Obstet Gynaecol Br Emp*, 1922; 29: 643
4. Jindal G, Kachhawa S, Meena GL et al: Uterus didelphys with unilateral obstructed hemivagina with hematometrocolpos and hematosalpinx with ipsilateral renal agenesis. *J Hum Reprod Sci*, 2009; 2: 87–89
5. Ballesio L, Andreoli C, De Cicco ML et al: Hematocolpos in double vagina associated with uterus didelphys: US and MR findings. *Eur J Radiol*, 2003; 45: 150–53
6. Troiano RN: Magnetic resonance imaging of mullerian duct anomalies of the uterus. *Top Magn Reson Imaging*, 2003; 14: 269–79
7. Shavell VI, Montgomery SE, Johnson SC et al: Complete septate uterus, obstructed hemivagina, and ipsilateral renal anomaly: Pregnancy course complicated by a rare urogenital anomaly. *Arch Gynecol Obstet*, 2009; 280: 449–52
8. Vercellini P, Daguati R, Somigliana E et al: A symmetric lateral distribution of obstructed hemivagina and renal agenesis in women with uterus didelphys: Institutional case series and a systematic literature review. *Fertil Steril*, 2007; 87: 719–24
9. Prada Arias M, Muguerra Vellibre R, Montero Sánchez M et al: Uterus didelphys with obstructed hemivagina and multicystic dysplastic kidney. *Eur J Pediatr Surg*, 2005; 15: 441–45
10. Jeong J-H, Kim Y-J, Chang C-H et al: A case of Herlyn-Werner-Wunderlich syndrome with recurrent hematopyometra. *J Womens Med*, 2009; 2: 77–80
11. Orazi C, Lucchetti MC, Schingo PM et al: Herlyn-Werner-Wunderlich syndrome: Uterus didelphys, blind hemivagina and ipsilateral renal agenesis. Sonographic and MR findings in 11 cases. *Pediatr Radiol*, 2007; 37(7): 657–65