



Received: 2016.07.17
Accepted: 2016.08.12
Published: 2017.04.22

Authors' Contribution:

- A** Study Design
- B** Data Collection
- C** Statistical Analysis
- D** Data Interpretation
- E** Manuscript Preparation
- F** Literature Search
- G** Funds Collection

Imaging of Complications After Limb Prostheses Implantation in Children with Bone Tumors

Beata Iwanowska^{ABCDEF}, Hanna Brągoszewska^{BCD}, Jarosław Mądzik^{BCD},
Sylvia Szkudlińska-Pawlak^{BCD}, Izabela Kopyś-Wiszniewska^{BCD},
Małgorzata Jastrzębska^{BCD}, Barbara Kowalska^{BCD}, Maria Uliasz^{BCD},
Monika Bekiesińska-Figatowska^{AEEFG}

Department of Diagnostic Imaging, Institute of Mother and Child, Warsaw, Poland

Author's address: Beata Iwanowska, Department of Imaging Diagnostics, Institute of Mother and Child, Kasprzaka 17a Str., 01-211 Warsaw, Poland, e-mail: beaiwanowska@imid.med.pl

Source of support: The work was supported by an internal grant from the Institute of Mother and Child in Warsaw, Poland

Summary

Background:

Tumors of the developmental age are an important problem in clinical practice. Primary bone tumors constitute 1–1.5% of all tumors, and 7% of all tumors diagnosed in the developmental age. The aim of the study was to assess the capabilities of imaging methods in diagnosing complications of limb endoprostheses in children with osteoarticular tumors.

Material/Methods:

We included 155 patients with limb endoprostheses, aged 7–26 years. There were 113 patients with knee prostheses, 1 patient with bilateral knee prostheses, 16 patients with shoulder prostheses, 14 patients with hip prostheses, 11 patients with hip and knee prostheses, and 1 patient with a femoral prosthesis. All patients underwent plain radiography and an ultrasound study.

Results:

Complications were found in 50 patients (32% of all patients). The following complications were seen – inflammatory changes in soft tissues and bones (12 patients, 7.7%), stump fractures (11 patients, 7%), lack of elongation effect or shortening of the prosthesis (7 patients, 4.5%), prosthesis fractures (4 patients, 2.5%), crural fractures (4 patients, 2.5%), loosening of the prosthesis (3 patients, 1.9%), joint dislocation (2 patients, 1.3%), stump and prosthesis fracture (1 patient, 0.6%) and local recurrence (6 patients, 3.9%). Prostheses were exchanged for the following reasons – fractures (5 patients, 3.2%), inflammation (2 patients with 3 exchanges, 1.9%). Local recurrence and inflammation were confirmed by a biopsy.

Conclusions:

Radiography and ultrasonography are of crucial importance in monitoring patients after implantation of limb endoprostheses. The findings did not require confirmation in additional studies: CT and MRI. Suspicion of local recurrence and inflammation required a biopsy confirmation.

MeSH Keywords:

Equipment Failure Analysis • Neoplasms, Bone Tissue • Postoperative Complications • Ultrasonography • X-Ray Film

PDF file:

<http://www.polradiol.com/abstract/index/idArt/900644>

Background

Primary bone cancers are rare. They constitute approximately 7% of all cancers in children. The highest incidence is in the second and third decades of life. The most commonly found cancers of the developmental age include osteogenic sarcoma and Ewing's sarcoma. Other cancers, including

chondrosarcoma, malignant vascular tumors, osteoclastoma and malignant fibrohistiocytic neoplasms occur rarely. A common tumor found in the second decade of life is the benign osteblastoma, which can also become malignant and cause pulmonary metastases (aggressive osteoblastoma).

Table 1. Complications after implantation of limb endoprostheses in the studied patients.

Complication	Case number	Percentage of the studied group	Percentage of complications
Inflammatory lesions in soft tissues and bones (Figure 1A, 1B)	12	7.7	24
Stump fracture (Figures 2, 3)	11	7	22
No elongation or shortening of prosthesis	7	4.5	14
Prosthesis fracture (Figure 4)	4	2.5	8
Fracture of other bone in the operated limb	4	2.5	8
Loosening of endoprosthesis (Figure 5)	3	1.9	6
Joint dislocation (Figure 6)	2	1.3	4
Stump and endoprosthesis fracture	1	0.6	2
Local recurrence (Figures 7, 8A, 8B)	6	3.9	12
Total	50	31.9	100

The following imaging studies can help diagnose and stage bone tumors:

- Plain radiography – performed in two planes. It assesses structural changes of bones (injury, neoplasia, periosteal reactions characteristic of cancer).
- Ultrasonography – assesses soft tissue involvement, tumor vascularity, relation of the tumor to blood vessels, lymph node enlargement
- Computed tomography (CT) – precisely assesses the presence and scope of bone damage, new bone formation, periosteal reactions and involvement of surrounding tissues and bone marrow
- Magnetic resonance imaging (MRI) – the preferred modality, as it can precisely assess bone marrow involvement and is not associated with radiation exposure and iodinated contrast agents
- Bone scintigraphy – it is sensitive but not specific, used for the assessment of local tissues around the tumor as well as to look for local and distal metastases.

The above-mentioned methods are used for diagnosing, treating and monitoring of osteoarticular tumors after treatment. They assess healing, complications and recurrence.

The basic imaging studies include plain radiography in two projections and ultrasonography of the limb. MRI and CT are used in order to further assess the involvement of bone marrow and surrounding tissues.

Similarly, plain radiography is an essential study used during management, in order to evaluate structural changes of the tumor in response to chemotherapy and before surgery. On ultrasound, tumor regression in soft tissues can be assessed. Moreover, follow-up MRI studies are also performed [1,2]. The scope of surgery depends on the tumor size and its relationship to the surrounding tissues. The aim of surgery is a total resection with a margin of healthy tissue. Limb-sparing surgery is now the mainstay of treatment, which is enabled by endoprostheses, especially growing prostheses [3]. After resection and endoprosthesis

implantation, plain radiography and ultrasonography are routinely used.

The aim of this study was to assess the capabilities of the two simplest, most cost-effective and safest imaging modalities used to look for complications of limb endoprosthesis implantation in children with bone tumors.

Material and Methods

We included 155 patients from the Department of Oncological Surgery of Children and Adolescents, Institute of Mother and Child (IMC), Warsaw, Poland, who underwent implantation of endoprostheses between 2000 and 2008 and were diagnosed in the Department of Diagnostic Imaging, IMC. The reasons for implanting endoprostheses were – osteosarcoma (122 patients), Ewing's sarcoma (16 patients), chondrosarcoma (14 patients), PNET (3 patients) and small cell carcinoma (1 patient). The age ranged from 6 to 26 years (mean age of 15 years). There were 65 girls and 90 boys. The following prostheses were implanted – knee prosthesis (113 patients), bilateral knee prosthesis (1 patient), shoulder prosthesis (16 patients), hip prosthesis (14 patients), hip and knee prosthesis (11 patients) and femoral prosthesis (1 patient).

All patients underwent radiographic and ultrasound studies.

Results

Following implantation of prostheses, complications were found in 50 patients (32%). They are presented in Table 1.

Inflammation and recurrence were confirmed by a biopsy.

Prostheses were exchanged in 5 patients because of fracture (3.2%) and in 3 patients (1.9%) because of inflammation – one patient underwent two exchanges.

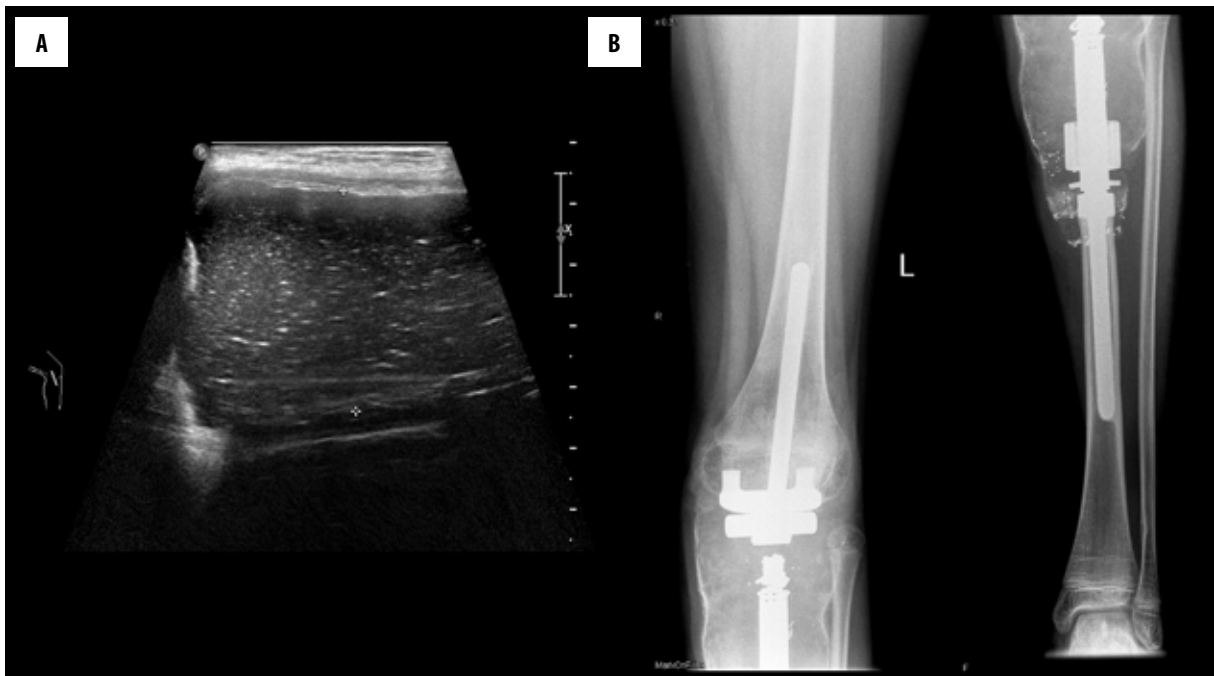


Figure 1. 10-year-old boy with osteosarcoma of the tibia one year after implantation of knee prosthesis. (A) Ultrasonography: fluid collection at the level of the knee joint, thickened synovium and soft tissues along the stem of the prosthesis. (B) X-ray: knee prosthesis in the normal position. Thickened soft tissues at the level of the knee joint and along the prosthesis, peripherally calcified. Inflammatory changes were diagnosed.

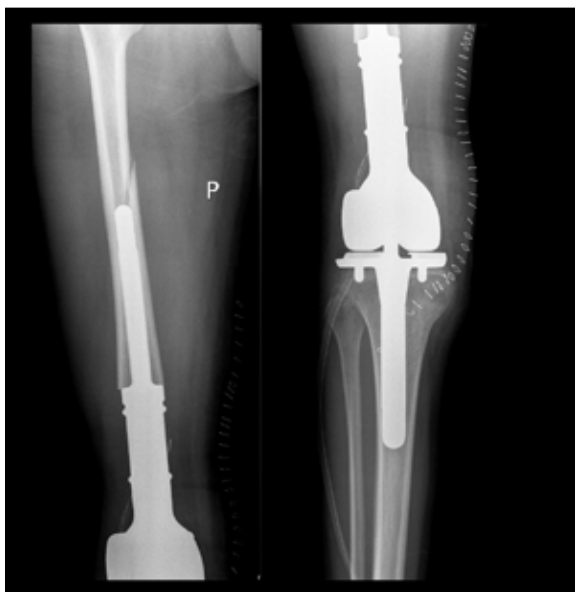

Figure 2. 17-year-old boy with femoral osteosarcoma one year after implantation of endoprosthesis. X-ray: fracture of the femoral stump.

Discussion

According to the report of the United Nations Scientific Committee on the Effects of Atomic Radiation (UNSCEAR), the widespread belief that children are generally 2–3 times more sensitive to ionizing radiation than adults in the context of malignant tumors formation is not fully correct, since in 15% of cancers (e.g. colon cancer) susceptibility of children is comparable to that of adults. Similarly, in 10%

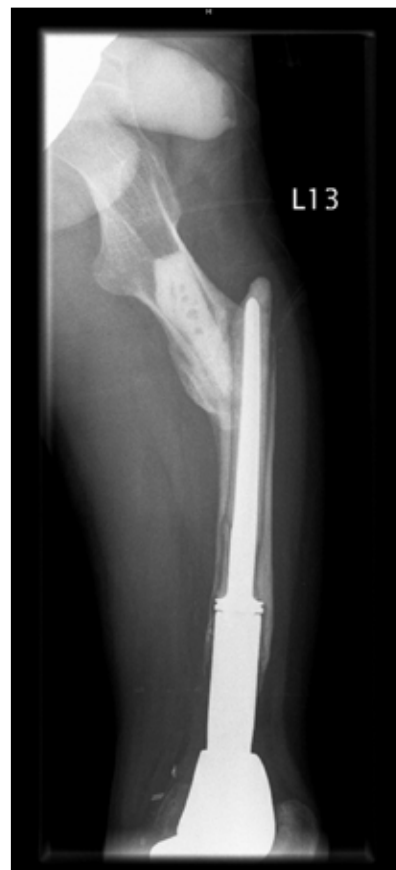

Figure 3. 17-year-old boy with femoral osteosarcoma one month after implantation of endoprosthesis. X-ray: fracture of the femoral stump.

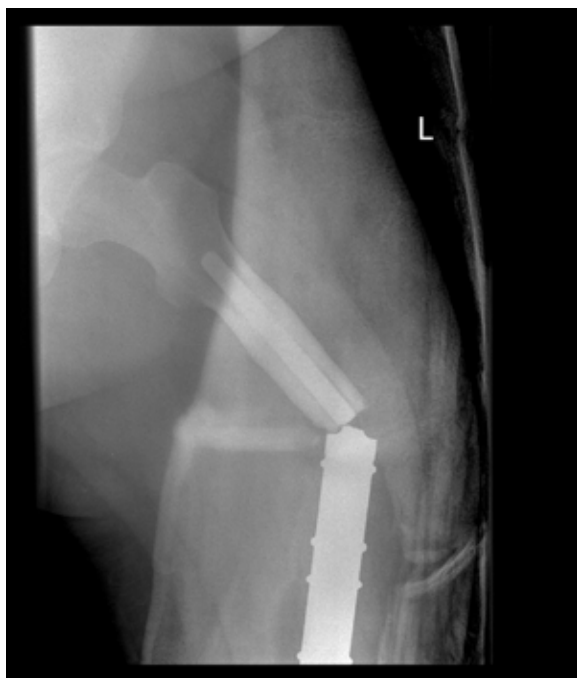

Figure 4. 16-year-old boy with femoral osteosarcoma six years after implantation of endoprosthesis presenting after trauma. X-ray: fracture of the prosthesis.

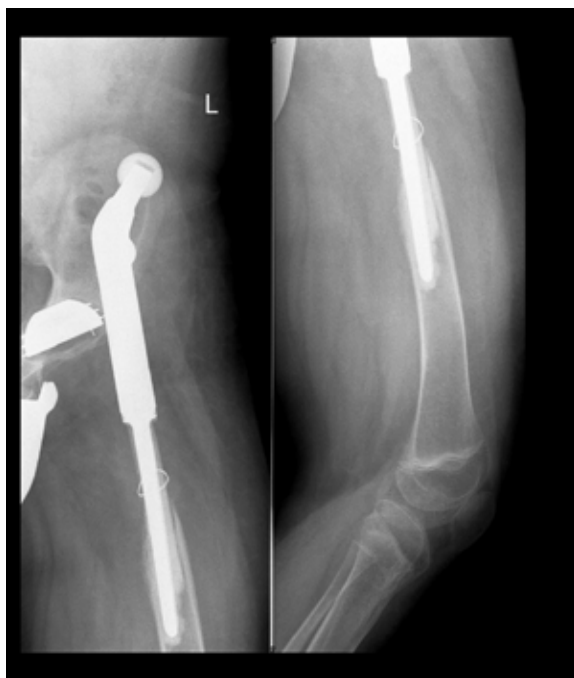

Figure 6. 19-year-old boy with femoral chondrosarcoma one year after implantation of hip endoprosthesis. X-ray: joint dislocation.

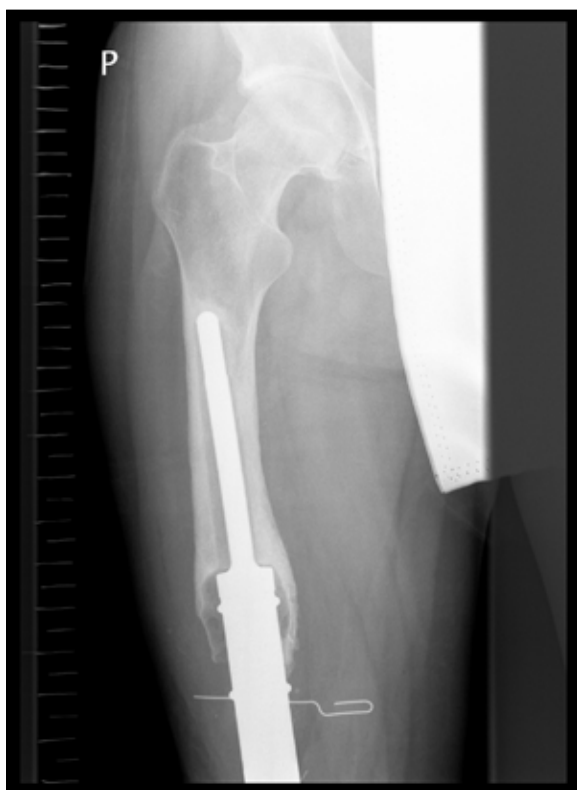

Figure 5. 26-year-old patient with femoral osteosarcoma five years after implantation of endoprosthesis. X-ray: loosening of the prosthesis at the level of the femoral stump.

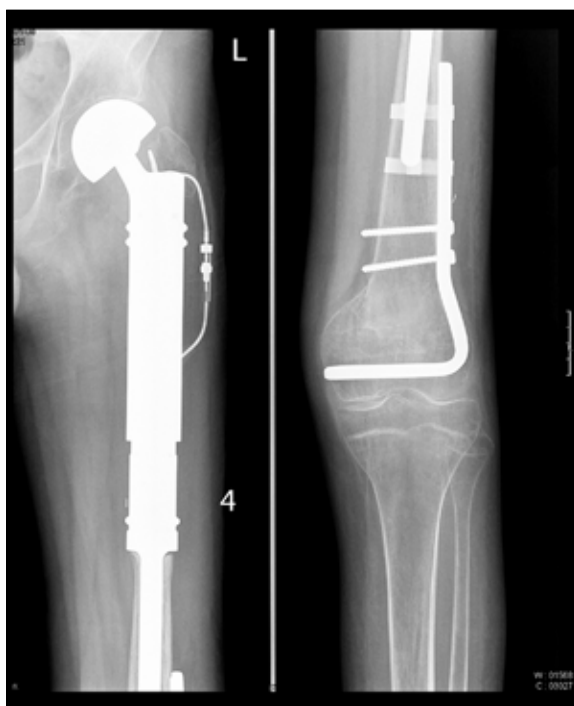

Figure 7. 16-year-old boy with Ewing's sarcoma one year after implantation of hip endoprosthesis. X-ray: osteolytic area in the medial femoral condyle. Disease recurrence was diagnosed.

of cancers (e.g. lung cancer), radiation exposure in children is less significant than in adults [4]. However, it is certain that 25% of cancers in children are associated with a

greater sensitivity to radiation. These cancers include leukemia, thyroid cancer, skin cancer and brain cancer [4,5]. Children with malignant tumors are frequently exposed to imaging studies associated with ionizing radiation exposure. For instance, in our patients with bone tumors, we

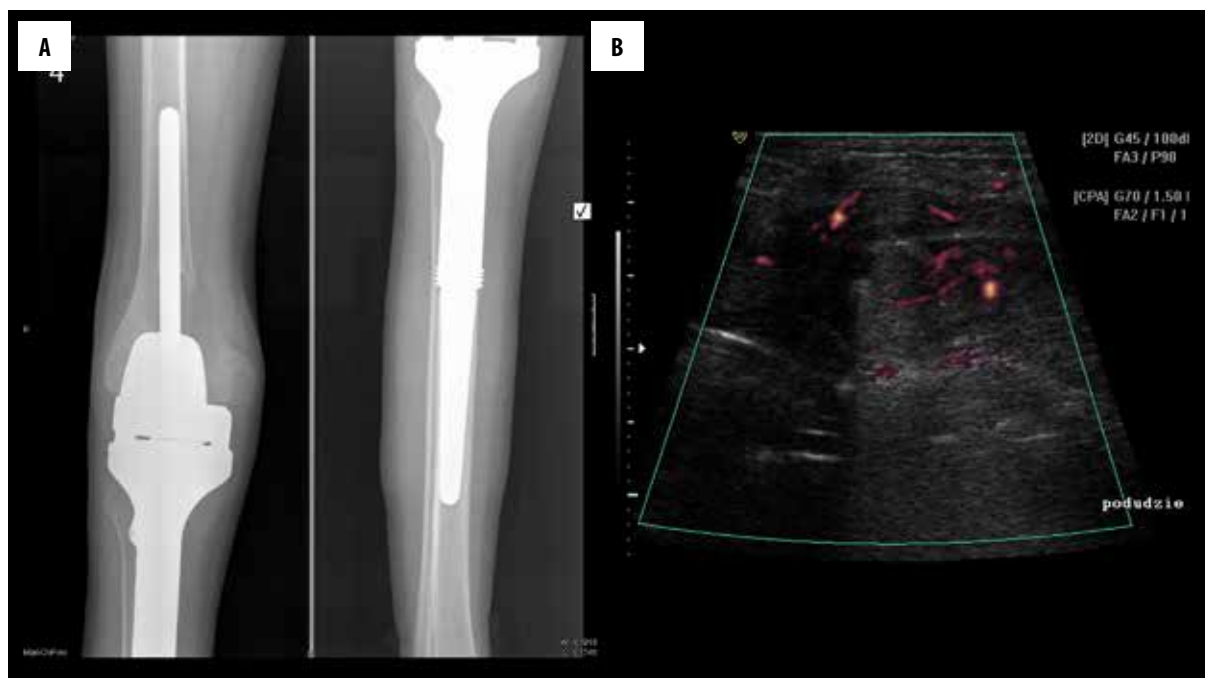


Figure 8. 15-year-old boy with tibial osteosarcoma one year after implantation of prosthesis. (A) X-ray: osteolytic defect in the medial femoral condyle. (B) Ultrasonography: solid tumor next to the defect with rich vascular supply. Disease recurrence in the femur was diagnosed.

repeatedly performed plain radiography and chest CT to look for lung metastases, which resulted in a high accumulated radiation dose. It has been demonstrated that in children who receive approximately 50 mGy of radiation the risk of leukemia is increased three-fold [6].

The aim of treatment in the case of cancer is a complete remission and therefore all care should be given to minimize the necessary dose of radiation, which can negatively influence future life of patients. Therefore, in children the diagnostic work-up for bone tumors includes plain radiography, ultrasonography and MRI, and CT is only performed to look for lung metastases. Similarly, we wanted to minimize radiation exposure in children in whom we looked for complications of limb endoprostheses. Therefore, we used only radiography and ultrasonography.

Despite its complications, implantation of limb endoprostheses, especially growing endoprostheses, is the method of choice for treating patients with bone tumors, which assures comfortable and optimal everyday functioning. The possible complications of limb endoprostheses have been described in detail [7], but their imaging is less well known [8].

According to some authors, complications occur in up to 85% of patients over a period of 5 years since implantation, including infections (4–12%), loosening of prosthesis (4–8%), fractures (1.6–4%) and local recurrence (4%) [9,10]. In our patients, only 32% had complications with a follow-up of up to 8 years.

Mechanical complications of endoprostheses, i.e. loosening, dislocation, fracture, are diagnosed solely based on radiography, which was also true in our study [8]. In the available literature, there are no definite criteria of a loosened

prosthesis in children with bone tumors after limb-sparing surgery. Some reports on cancer patients use orthopedic criteria that have been created for patients after hip replacement. It is normal to see a narrow zone of bone radiolucency (smaller than 2 mm) around the endoprosthesis, which can be accompanied by thin, sclerotic rim, unless there is no progression over 2 years. If this zone becomes wider, with a resultant increased bone radiopacity and with increased cortical layer, a loosening of endoprosthesis can be a cause [11,12]. Moreover, plain radiography can show evident mechanical complications such as prosthesis dislocation or a change of its axis. Infections following prosthesis implantation are serious complications and often can prompt removal of the prosthesis, implantation of temporary prosthesis and long-term anti-inflammatory treatment. According to some authors, infections constitute 1–15% of all complications [13]. Infectious complications can be seen in the period from one month to 4 years after prosthesis implantation. The condition of soft tissues before surgery is important in this respect. The risk of infection is not related to the bone length than is resected [14]. After large reconstructive surgeries, the rate of infectious complications can be as high as 22.5% [15,16]. In our study, infectious complications were seen most frequently and were found in 7.7% of children, which constituted 24% of all complications.

Inflammatory complications and local recurrence were difficult to assess. These complications are assessed primarily with the use of ultrasound as the metal parts of endoprostheses produce artifacts in CT and MRI [8]. An ultrasound examination can help detect thickening of the synovial membrane with its increased vascularity, fluid collections, abscesses or disorganized tissue masses suggesting recurrence. The thickening of the synovial membrane with increased vascularity as well as enlarged regional lymph nodes can indicate an

inflammatory process. Often it is accompanied by fluid collections at the level of the prosthesis. Areas of dense, encapsulated fluid accompanied by enlarged lymph nodes can indicate abscess formation. Fluid collections can also appear when the operated limb is strained.

New abnormal tissue masses with a good vascular supply and abutting the stump as well as evidence of bone destruction suggest disease recurrence, which should prompt further work-up, including a biopsy. Naturally, inflammatory changes can also cause bone destruction and therefore a histopathological verification is necessary. Elevated levels of inflammatory markers can suggest an inflammatory process and not disease recurrence.

Currently, PET/CT is used widely; however, it cannot differentiate between inflammatory changes and disease recurrence. In a study of children with sarcomas of long bones and soft tissues, this method had 100% sensitivity and 92% specificity in recurrence detection, with the only false positive result attributed to an inflammatory process [16]. In order to reduce the dose of radiation, the

role of PET/MRI is emphasized (73% reduction). However, because of false positives in cases of inflammatory changes, biopsy is crucial. This approach was also applied in our study, and all patients with suspected inflammatory changes around the prosthesis or disease recurrence, based on ultrasonography, had a histopathological verification.

Conclusions

The safest, most cost-effective, simplest and serially used imaging modalities such as radiography and ultrasound play a crucial role in monitoring patients after limb prosthesis implantation. In our patients, complications found with the use of these methods were confirmed clinically and did not require further work-up with MRI or CT. The differentiation between inflammatory changes and disease recurrence had to be made based on a histopathological examination.

Conflict of interest

We do not declare conflict of interest.

References:

1. Wermeński K, Bragoszewska H, Romaniuk-Doroszevska A et al: Diagnostic imaging of primary malignant bone tumors in children (osteosarcoma, Ewing's sarcoma) – part I. *Pol J Radiol*, 2008; 73(1): 49–61
2. Wermeński K, Bragoszewska H, Romaniuk-Doroszevska A et al: Diagnostic imaging of primary malignant bone tumors in children (osteosarcoma, Ewing's sarcoma) – part II. *Pol J Radiol*, 2008; 73(2): 65–76
3. Hwang JS, Mehta AD, Yoon RS, Beebe KS: From amputation to limb salvage reconstruction: Evolution and role of the endoprosthesis in musculoskeletal oncology. *J OrthopTraumatol*, 2014; 15(2): 81–86
4. United Nations Scientific Committee on the Effects of Atomic Radiation. Scientific findings on effects of radiation exposure of children. Volume II, Annex B. Vienna: United Nations Scientific Committee on the Effects of Atomic Radiation; 2013. http://www.unscear.org/docs/reports/2013/UNSCEAR2013Report_AnnexB_Children_13-87320_Ebook_web.pdf.
5. Rehani M: Are children more sensitive to radiation than adults? *ESR@ Work*. European Society of Radiology newsletter, September 2013. http://www.myesr.org/html/img/pool/Radiation_Protection_ESR_Work_Sept_2013.pdf.
6. Pearce MS, Salotti JA, Little MP et al: Radiation exposure from CT scans in childhood and subsequent risk of leukaemia and brain tumours: A retrospective cohort study. *Lancet*, 2012; 380(9840): 499–505
7. Yang RS: Endoprosthesis-related complications after limb-salvage operation of malignant bone tumors around the knee. *Biomed Eng Appl Basis Commun*, 2004; 16: 133–42
8. Zbojniewicz AM, Sorge JL: Posttreatment imaging of pediatric musculoskeletal tumors. *Radiographics*, 2014; 34(3): 724–40
9. Graci C, Maccauro G, Muratori F et al: Infection following bone tumor resection and reconstruction with tumoral prostheses: A literature review. *Int J Immunopathol Pharmacol*, 2010; 23(4): 1005–13
10. Nystrom LM, Morcuende JA, Iowa JA: Expanding endoprosthesis for pediatric musculoskeletal malignancy: current concepts and results. University of Iowa Hospitals & Clinics, Iowa City, IA, USA. *Orthop J*, 2010; 30: 141–49
11. Pluot E, Davis ET, Revell M et al: Hip arthroplasty. II. Normal and abnormal radiographic findings. *Clin Radiol*, 2009; 64(10): 961–71
12. Manaster BJ: Total hip arthroplasty: radiographic evaluation. *Radiographics*, 1996; 16(3): 645–60
13. Hards J, Gebert C, Schwappach A et al: Characteristics and outcome of infections associated with tumor endoprostheses. *Trauma Surgery* © Springer-Verlag 2006, 10.1007/s00402-005-0009-1
14. Morii T, Yabe H, Morioka H et al: Postoperative deep infection in tumor endoprosthesis reconstruction around the knee. *Orthop Sci*, 2010; 15(3): 331–39
15. Witte D, Bernd L, Bruns J et al: Limb-salvage reconstruction with MUTARS hemipelvic endoprosthesis: A prospective multicenter study. *Eur J Surg Oncol*, 2009; 35(12): 1318–25
16. Jaiswal PK, Aston WJ, Grimer RJ et al: Peri-acetabular resection and endoprosthetic reconstruction for tumours of the acetabulum. *J Bone Joint Surg Br*, 2008; 90(9): 1222–27
17. Arush MW, Israel O, Postovsky S et al: Positron emission tomography/computed tomography with 18fluoro-deoxyglucose in the detection of local recurrence and distant metastases of pediatric sarcoma. *Pediatr Blood Cancer*, 2007; 49(7): 901–5
18. Schäfer JF, Gatidis S, Schmidt H et al: Simultaneous whole-body PET/MR imaging in comparison to PET/CT in pediatric oncology: Initial results. *Radiology*, 2014; 273(1): 220–31