

Original paper

Diagnostic performance of HyFoSy versus HSG for tubal patency: accuracy and agreement analysis

Shaymaa K. Abdulqader^{1,A,B,F,#}, Wassan Nori^{2,A,D,E,#}, Rajaa A. Mohammed^{3,D,E}, Wisam Akram^{2,F,G}, Nabeeha N. Akram^{4,C}

¹Department of Radiology, Al-Kindy College of Medicine, University of Baghdad, Baghdad, Iraq

²Department of Obstetrics and Gynecology, College of Medicine, Mustansiriyah University, Baghdad, Iraq

³College of Medicine, University of Fallujah, Al-Anbar, Iraq

⁴Department of Pediatrics, College of Medicine, Mustansiriyah University, Baghdad, Iraq

#These authors contributed equally to this work.

Abstract

Purpose: Tubal patency examination is an essential part of the infertility workup; hysterosalpingo-foam sonography (HyFoSy) is a recommended substitute for the standard hysterosalpingography (HSG). This study aimed to determine the diagnostic concordance of HyFoSy and HSG, as well as the impact of uterus position on test performance.

Material and methods: The prospective observational cohort study enrolled 80 infertile women referred for assessing tubal patency at Al Yarmouk Hospital. Recorded parameters included demographics (age, parity, uterus position) and the results of tubal patency testing (patent, unilateral, or bilateral blocked tubes). HyFoSy was performed first, followed by HSG.

Results: Age and parity were insignificant. HyFoSy showed a high degree of diagnostic concordance with HSG (85%), with a Cohen's κ coefficient of 0.3 (95% confidence interval, CI: 0.05-0.55). Gwet's agreement coefficient 1 was 0.84 (95%, CI: 0.74-0.94), indicating strong agreement. McNemar's test revealed significant systematic bias between the methods ($p < 0.001$), suggesting that HyFoSy and HSG are not interchangeable, which was further confirmed by Bland-Altman analysis showing a mean bias of +0.25 in favor of HyFoSy. The latter has a tendency to overestimate tubal patency among women with a retroverted uterus.

Conclusions: HyFoSy is a promising tool for use as a complementary infertility test, showing high concordance with HSG. However, it should not be used as a stand-in for HSG without clinical judgment, especially in women with a retroverted uterus. The best of both approaches may be provided by a hybrid strategy that uses HyFoSy as a first-line test and saves HSG for cases that are unclear or high-risk.

Key words: hysterosalpingography, hysterosalpingo-foam sonography, ExEm, tubal patency.

Introduction

Five to fifteen percent of couples worldwide are currently infertile, with female factors accounting for about 65% of cases [1]. Infections, endometriosis, prior surgery, and, in rare cases, fibromas or polyps, are the main causes

of tubal blockage, which accounts for 26% of female infertility [2]; 40% of female infertility cases are diagnosed with hysterosalpingography (HSG) or laparoscopic procedures, which are reported to be as accurate in determining uterine morphology [3].

Correspondence address:

Dr. Shaymaa Khalid Abdulqader, Department of Radiology, Al-Kindy College of Medicine, University of Baghdad, House 84, Lane 8, Block 645, Al-Adel District, Baghdad 10011, Iraq, e-mail: shaymaa.k@kmc.uobaghdad.edu.iq

Authors' contribution:

A Study design · B Data collection · C Statistical analysis · D Data interpretation · E Manuscript preparation · F Literature search · G Funds collection

Laparoscopy with dye chromopertubation – commonly known as the lap-and-dye test – is considered the gold standard for evaluating tubal patency. Despite its diagnostic accuracy, it is seldom used due to its invasive nature and high cost. As a result, HSG remains the most widely adopted method across many countries. HSG is recognized for being accurate, safe, efficient, and cost-effective. However, it comes with notable drawbacks that prompt the search for alternatives: it can be painful, involves the use of iodinated contrast agents, and exposes patients to ionizing radiation [4]. Transvaginal ultrasound alone cannot determine whether the fallopian tubes are patent. In contrast, hysterosalpingo contrast sonography (HyCoSy) is recognized as a sensitive and efficient method for evaluating tubal patency. It offers a quick, straightforward, and dependable screening process while simultaneously allowing assessment of the uterus and ovaries [5]. HyCoSy has been considered as a less painful alternative to HSG; it is a minimally invasive ultrasound-based procedure, typically performed by gynecologists, that eliminates the risks associated with iodinated contrast agents and exposure to ionizing radiation [2]. It involves transvaginal ultrasound-aided intrauterine contrast administration, allowing assessment of tubal patency and identification of gynecological conditions such as endometrial polyps, fibroids, and ovarian cysts, and evaluation of endometrial thickness [6]. Early contrast agents used in the procedure included saline or a mixture of air and saline. However, interpreting tubal patency with these agents required advanced skill due to the brief window during which the contrast could be visualized passing through the fallopian tubes [7]. Then, more echogenic contrast media such as Echovist Infuson and SonoVue were introduced, but they are either no longer marketed or not authorized for intrafallopian usage [8]. ExEm gel (GynaecologIQ), made of glycerol and hydroxyethylcellulose, was released in 2007. It is diluted with water, and when this solution is forced through small holes in tubes and syringes, foam is produced mechanically. In comparison to water, the diluted gel is sufficiently fluid to flow through patent tubes without being so viscous that the air bubbles stay suspended in it for an extended period. As a result, the foam mixture becomes more stable and can continue to be echogenic for roughly seven minutes, making it suitable for use as a contrast medium in hysterosalpingo-foam sonography (HyFoSy) [9].

Although many studies have shown comparable efficacy between HyFoSy and HSG, a critical knowledge gap remains in the current evidence [10,11].

There is no standardized protocol for bias estimation, and current methods do not adequately account for patient-specific factors, such as anatomical variations, that affect diagnostic concordance. The data on false positive HyFoSy findings are scarce, limiting evidence-based recommendations for routine test selection practice [12].

Furthermore, there is a lack of comparative data from Iraq, underscoring the need for regional validation to establish baseline diagnostic parameters.

This study aimed to assess the diagnostic agreement between HyFoSy and HSG as a test for tubal patency assessment via prevalence-adjusted statistical methods to define systematic bias. The secondary aim was to determine the impact of patent criteria, specifically the position of the uterus, on test concordance, to build a permanent regional dataset for future validation. A deeper insight into the magnitude and the direction of diagnostic concordance between the two tests is crucial for developing an evidence-based clinical algorithm that balances diagnostic accuracy with patient comfort.

Material and methods

Participants and ethics

This prospective comparative diagnostic accuracy study was performed in the Radiology Department of Al-Yarmouk Teaching Hospital for 5 months (from March to July, 2025). The Ethical Committee of Al-Kindy College of Medicine issued the study approval No. 217 in 30/04/2025. All the study methods were conducted in line with the Declaration of Helsinki. Written informed consent was obtained from all participants after they were informed of the study's aim, procedure, and potential radiation risks. All participants were informed that they had the right to withdraw without compromising their right to clinical care.

Consecutive sampling was used to enroll infertile women referred for a traditional HSG examination as part of an infertility workup. Patients who consented to undergo both examinations (HSG and HyFoSy) were included in the study.

Inclusion criteria

- Infertile female patients aged from 18 to 45 years old were invited; infertility was defined as failure to achieve pregnancy following 1 year of regular unprotected sex (reduced to 6 months for women older than 35 years) of regular unprotected sex [13].
- Clinical indication for tubal patency assessment.
- The patient should have documented normal ovulation, although HSG is often performed in women with concurrent ovulatory problems in practice; we adopted this criterion to create a more homogeneous population in which infertility is attributable primarily to tubal factors.
- Regular baseline renal function test; creatinine < 1.2 mg/dl.

Exclusion criteria

- Participants with a history of contrast allergic reaction or intolerance to one of the two examinations were excluded from the study.

- Active pelvic inflammatory disease or severe systemic illness.
- Unexplained abnormal uterine bleeding.

Both tubal patency assessments were conducted within two weeks from the first day of menstruation, preferably between days 6 and 10.

Operator qualification and blindness, outcome measured

The physician conducting the test was a certified radiologist with more than 5 years of expertise in reproductive imaging in the presence of a gynecologist. The radiologist conducting the HSG was unaware of the HyFoSy results, and likewise, the HyFoSy examiner was blinded to the HSG findings. The outcomes of both tests were categorized as normal, unilateral tubal pathology, or bilateral tubal pathology.

Imaging protocol details

- Beginning with the HyFoSy examination, the patient is put in a lithotomy position, and after sterilization of the genital area, a suitable size Cusco's speculum is introduced to visualize the vagina and cervical canal. A small cervical catheter is introduced through the cervix and connected to a syringe containing 10 cc of foam, which is then injected into the uterus (Figure 1). A foam-filled syringe is attached to this applicator. In a 10 ml syringe, 5 ml of pure water and 5 ml of ExEm-gel (IQ Medical Ventures BV, Delft, The Netherlands; containing hydroxyethyl cellulose and glycerol) are thoroughly mixed to generate this foam, producing foam that is stable enough to exhibit echogenicity for at least five minutes and that has enough fluid to flow through patent tubes. Transvaginal ultrasound is performed to determine whether the fallopian tubes are patent during the foam infusion into the uterus. This foam material appears highly echogenic, outlining the endometrial cavity, one or both fallopian tubes, and spills within the pelvic cavity (Figure 2).
- During the HSG examination, a balloon catheter is placed on the cervix, which is used to inject roughly 10 cc of water-soluble iodinated contrast medium into




Figure 1. Two syringes of foam and water (orange arrows) connected by a connector (green arrow) for mixing. The cervical applicator (blue arrow) is used to introduce the material to the cervix and uterus

the uterus and fallopian tubes, depending on the local protocol of our hospital. The flow of the contrast medium within the uterus and the tubes can be visualized by exposing the pelvic area to a series of about six radiographs to determine their patency while the contrast medium is inserted into the uterus and fallopian tubes (Figure 2).

- Both examinations (HSG and HyFoSy) were conducted in random order throughout the follicular phase of the same menstrual cycle (5th to 11th cycle day). The physicians were blinded to the results of the previously performed examination, according to the gold standard FOAM study protocol, which stated that conducting both tests within the same cycle does not impact the visible tubal patency compared with each method alone [14].

Sample size calculation

The sample size was determined according to prior studies, which reported agreement rates between the HyFoSy and HSG tubal patency tests [15,16].

A Cohen's kappa (κ) coefficient of 0.7 was targeted, which is interpreted as substantial agreement compared to the null hypothesis of 0.4, interpreted as moderate agreement [17]. With an α value of 0.05 and a statistical power of 80%, the calculation yielded a required sample size of 72 participants. To address potential technical failure, patient withdrawal, and subgroup analysis, we opted to enroll 80 participants.

Statistical methods

Data were analyzed by SPSS 26, and baseline criteria were presented as counts and percentages. Fisher's exact test

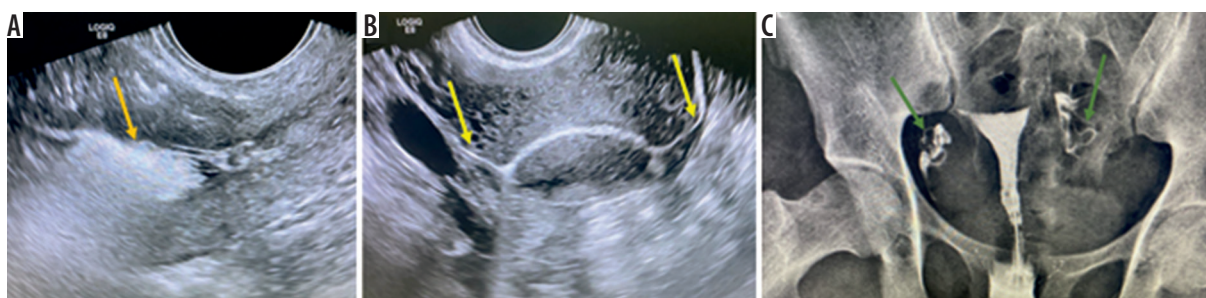

Figure 2. Transvaginal ultrasound images after injection of the foam into the uterus. A) Echogenic foam material outlining the endometrial cavity (orange arrow). B) Spillage of ultrasonic contrast in both patent tubes (yellow arrows). C) Hysterosalpingography of the same patient showing patency of both tubes (green arrows)

was used to examine the association between categorical variables and diagnostic concordance, given the small sample size. We evaluated the diagnostic agreement between HyFoSy and HSG using the overall agreement percentage, Cohen's κ coefficient for chance-corrected agreement, and Gwet's agreement coefficient 1 (AC1) to adjust for prevalence bias. McNemar's test examined systematic differences between the two paired methods. Positive and negative agreement proportions were added to the calculations. A Bland-Altman analysis evaluated agreement across the ranges of the tubal patency score. A $p < 0.05$ was set as significant for all tests.

Results

A total of 80 women of childbearing age were included in this study, with the majority, 64 (80%), aged less than 35 years, and 48 (60%) were nulliparous. The uterine position was anteverted in 64 (80%) vs. 16 (20%) that were retroverted in the included sample. HyFoSy shows high diagnostic concordance when compared to HSG, with concordance demonstrated in 68 (85%) women, as shown in Table 1 and Figure 3.

Overall, HyFoSy and HSG showed concordant findings in 85% of the patients. Uterine position significantly affected the agreement rates ($p = 0.028$). Anteverted (AV) uterus showed a meaningfully high concordance (88.2%) vs. retroverted (RV) uterus (33.3%). Age and parity showed no significant associations (Table 2).

Both methods agreed on bilateral tubal patency in 70% of the cases. Interestingly, no bilateral non-patent cases were diagnosed by either method, which hinders the assessment of negative agreement (Table 3).

The measurement of agreement showed an overall 85% agreement between the two methods. Cohen's κ was 0.3 (95% CI: 0.05-0.55), indicating fair agreement and suggesting an influence of the low prevalence of negative findings. Gwet's AC1 coefficient was 0.84, indicating strong agree-

Table 1. Clinical and anatomical characteristics of the studied sample ($N = 80$)

Variable	<i>n</i> (%)
Age	
≤ 35 years	64 (80)
> 35 years	16 (20)
Parity	
Yes	32 (40)
No	48 (60)
Uterus	
AV	64 (80)
RV	16 (20)
Diagnostic accuracy	
Concordance	68 (85)
Discordance	12 (15)

AV – anteverted uterus, RV – retroverted uterus

ment (95% CI: 0.74-0.94) after adjusting for prevalence bias. McNemar's test confirmed a significant systematic bias between the two methods ($p < 0.001$), suggesting that the interchangeability of the two methods has no role (Table 4).

The Bland-Altman plot showed a mean bias of +0.25 with HyFoSy, with a tendency to overestimate tubal patency versus HSG. Agreement's limits were -0.98 to +1.48, implying substantial inter-method variability, which suggests that both methods yield nonequivalent measures (Figure 4).

Table 3 provides the raw cross-tabulation of findings on a per-patient basis, showing how the bilateral tubal status classifications compare between the two methods. Table 4 presents statistical agreement measures using per-tube analysis, where each of the 160 tubes (from 80 patients) is evaluated independently for patency. Table 5 presents diagnostic test performance using per-patient

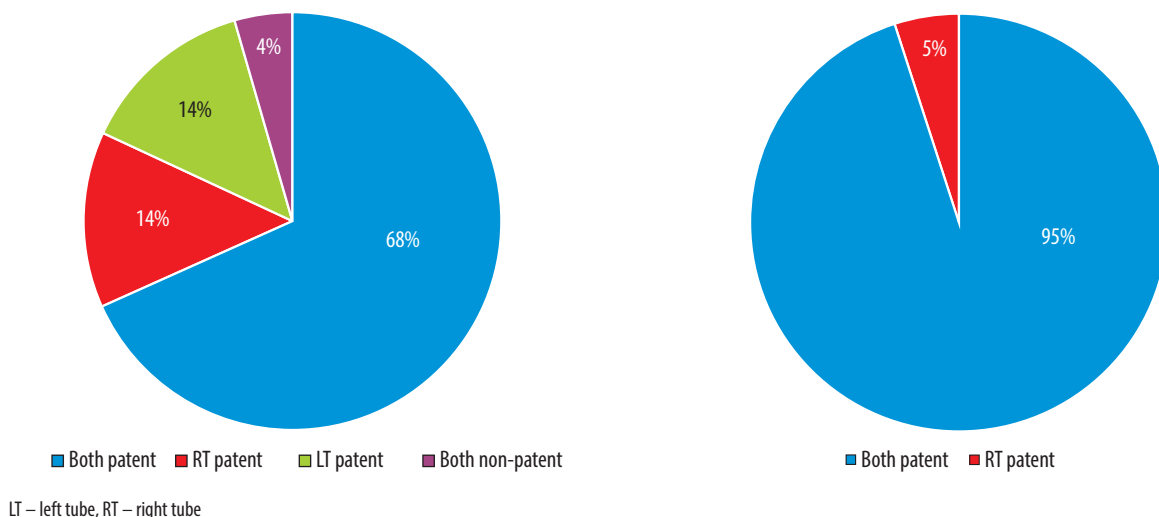


Figure 3. Diagnostic concordance between (A) hysterosalpingo-foam sonography (HyFoSy) and (B) hysterosalpingography (HSG) in tubal patency

Table 2. Diagnostic agreement between hysterosalpingo-foam sonography (HyFoSy) and hysterosalpingography (HSG) by patient characteristics

Variables	Diagnostic concordance (n = 68)	Diagnostic discordance (n = 12)	Odds ratio (95% CI)	p-value (Fisher's exact test)
Age, n (%)				
< 35 years	56 (82.4)	8 (66.7)	2.09 (0.65-6.74)	0.509
> 35 years	12 (17.6)	4 (33.3)	Reference	
Parity, n (%)				
Yes	28 (41.2)	4 (33.3)	1.38 (0.38-4.94)	0.998
No	40 (58.8)	8 (66.7)	Reference	
Uterus position, n (%)				
AV	60 (88.2)	4 (33.3)	15.0 (3.67-61.37)	0.028*
RV	8 (11.8)	8 (66.7)	Reference	

*Statistically significant.

AV – anteverted uterus, CI – confidence interval, RV – retroverted uterus

Table 3. Cross-tabulation of tubal patency findings between the two methods (per-patient analysis, N = 80)

HyFoSy results	HSG: both patent, n (%)	HSG: unilateral patent, n (%)	HSG: both non-patent, n (%)	Total, N (%)
Both patent	56 (70.0)*	16 (20.0)†	4 (5.0)†	76 (95.0)
Unilateral patent	4 (5.0)†	0 (0.0)	0 (0.0)	4 (5.0)
Both non-patent	0 (0.0)	0 (0.0)	0 (0.0)	0 (0.0)
Total	60 (75.0)	16 (20.0)	4 (5.0)	80 (100.0)

Note. This table presents a per-patient analysis where each patient's bilateral tubal status is categorized. HSG was used as the reference standard.

*Perfect agreement. †Disagreement between methods.

HSG – hysterosalpingography, HyFoSy – hysterosalpingo-foam sonography

Table 4. Statistical measure of agreement between hysterosalpingo-foam sonography (HyFoSy) and hysterosalpingography (HSG) (per-tube analysis, N = 160 tubes)

Measure	Value	95% CI
Overall agreement (%)	68/80 (85)	75.9-91.8
Cohen κ	0.30 (fair)	0.05-0.55
Gwet's AC1	0.84 (strong)	0.74-0.94
McNemar's test	p < 0.001	–
Positive agreement (%)	73.7	–
Negative agreement	Not estimable	–

Note 1. Agreement statistics are based on per-tube analysis (160 tubes from 80 patients). Each tube was classified as either patent or non-patent. The overall agreement of 85% indicates that 136 out of 160 tubes (68 out of 80 patients with bilateral agreement) showed concordant results between HyFoSy and HSG.

Note 2. Clarification on overall agreement: 68/80 (85%) represents patients where there was complete bilateral agreement (both tubes showed the same result on both tests). When calculated per tube, this translates to 136/160 tubes (85%) showing concordant findings.

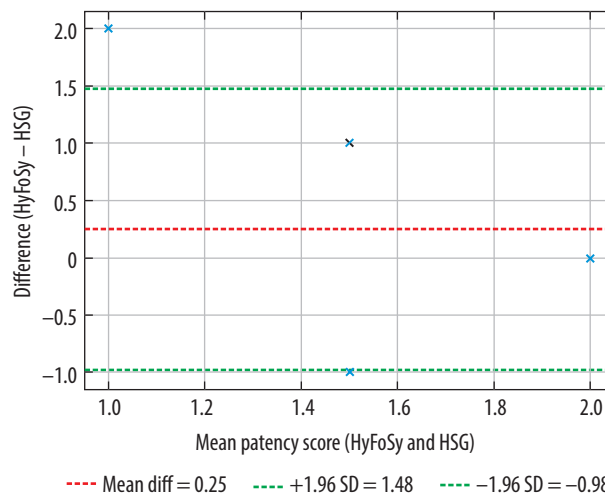


Figure 4. Bland-Altman plot; hysterosalpingo-foam sonography (HyFoSy) vs. hysterosalpingography (HSG) tubal patency score. Blue star markers represent individual paired observations, with each point indicating agreement between HyFoSy and HSG tubal patency scores for a single assessment. The vertical position reflects the difference between the methods, while the horizontal position represents their mean value

Table 5. Summary of diagnostic performance of hysterosalpingo-foam sonography (HyFoSy) compared to hysterosalpingography (HSG) in detecting tubal patency (per-patient analysis, N = 80)

Parameter	True positive	False positive	True negative	False negative	Sensitivity	Specificity	PPV	NPV	Accuracy
HyFoSy vs. HSG	56	20	0	4	93.3%	0%*	73.7%	0%*	70.0%

*Specificity and negative predictive value (NPV) could not be reliably estimated because no true negative cases were identified in the study cohort.

NPV – negative predictive value, PPV – positive predictive value

analysis, specifically evaluating HyFoSy's ability to detect bilateral tubal patency when compared to HSG as the reference standard.

The different units of analysis (per tube vs. per patient) explain why the total agreement in Table 4 (68/80 patients = 85%) differs from the distribution shown in Table 5, where only cases with bilateral patency agreement (56 patients) are counted as true positives.

Discussion

Tubal patency assessment is a cornerstone in infertility workups. While HSG is considered the gold standard, HyFoSy has emerged as a promising alternative, offering comparable diagnostic accuracy with greater patient comfort and procedural simplicity [6]. ExEm gel is safe, with no adverse effect on blastocyst development [4]. Unlike laparoscopy, which carries inherent risks associated with surgery and anesthesia, or HSG, which uses iodinated contrast agents that may trigger allergic reactions, in addition to radiation risk, HyFoSy provides a safer, less invasive alternative [2].

This study examined the overall concordance between HyFoSy and HSG in testing tubal patency, revealing a high concordance rate of 85% and a Cohen's κ of 0.30 with a 95% CI of 0.05 to 0.55. This finding was further confirmed by Gwet's AC1, which indicated strong agreement (0.84). In evaluating tubal patency, HyFoSy and HSG have a fair agreement. These results align with findings from studies by van Welie *et al.* [14], Emanuel *et al.* [17], Tsakos *et al.* [10], and Ramos *et al.* [15], as presented in Table 6.

The analysis showed that the HyFoSy and HSG test reliability was not affected by patient age or parity; both showed no influence on the agreement, in line with earlier works [11,15].

Li *et al.* [18] reported no significant correlation between primary or secondary infertility regarding fallopian tube visualization. A woman's status as multiparous or nulliparous had no bearing on the procedure's success, tolerability, or diagnostic performance. This could indicate that parity has little bearing on contrast flow, tubal visualization, or patient discomfort during HyFoSy.

The current results confirmed that the test agreement was reduced in RV uteri to 33%, with a p -value of 0.001, which underscores the uterine position as a key determinant in the accuracy of the HyFoSy test.

This may be due to many factors. For example, a uterus that is sharply retroverted may make cervical catheterization more difficult and raise the possibility of less than ideal contrast flow. The retroverted uterus also affects the trajectory of foam contrast, which may result in false negatives or poor fallopian tube visualization, so to see the tubes clearly in retroverted uteri, the sonographer may need to make significant adjustments to the probe orientation [19].

Li *et al.* [18] stated that the uterine position, uterine angle, and ovarian position all affect the visualization of the fallopian tubes, in good agreement with our results. Bohiltea *et al.* [12] recommended a wedge-shaped pad or a special gynecological table to ensure a gynecological position that is as close to 45° as possible to the Trendelenburg position to reorient the fallopian tubes as anatomically as possible.

Overestimation of tubal patency has clinical implications: the patient will experience delayed referral for definitive diagnosis and undergo a misguided treatment strategy that will only prolong the infertility period, with associated consequences [20].

We found that bilateral tubal patency in both examinations was 70% (perfect agreement) of cases in both

Table 6. Agreement between hysterosalpingo-foam sonography (HyFoSy) and hysterosalpingography (HSG) according to previous studies

Study/year	Study type, No. of participants	Agreement	Interpretation
Van Welie <i>et al.</i> (2022) [14]	RCT, 1026	~84%	HyFoSy was non-inferior to HSG in guiding fertility management; however, discordance was noted in ~16% of cases
Emanuel <i>et al.</i> (2011) [17]	Prospective observational cohort study, 72	78%	Discordance in 7% of cases; HyFoSy avoided HSG in most patients, showing good feasibility
Tsakos <i>et al.</i> (2023) [10]	Systemic review and meta-analysis, 1433	Fair agreement The analysis showed a Cohen's κ value of 0.39	Meta-analysis showed HyFoSy was less painful and more reliable than the HSG
Ramos <i>et al.</i> (2021) [15]	Prospective observational cohort study, 106	Moderate agreement HyFoSy showed total concordance with HSG in 72.6% of cases and total discordance in 4.7% Cohen's κ = 0.57	HyFoSy is a useful method for determining tubal patency; it might be regarded as a viable substitute for HSG in terms of precision and efficacy in patients with minimal tubal disease risk

RCT – randomized controlled trial

HSG and HyFoSy. In comparison, Exacoustos *et al.* [21] observed 81% bilateral patent tubes. This disparity could be due to the use of 3D ultrasound compared with the 2D ultrasound we used.

The Bland-Altman plot shows a mean bias of +0.25 and wide limits of agreement (-0.98 to +1.48), suggesting that HyFoSy tends to overestimate tubal patency compared to HSG, and the variability between methods is substantial enough to question their interchangeability.

The study results of Ramos *et al.* [15] and Grigovich *et al.* [22] aligned with ours; they stated that HSG remains the reference standard due to its ability to detect subtle tubal pathology, while HyFoSy is more patient-friendly but may miss certain structural abnormalities that HSG can detect, contributing to inter-method variability.

Several factors may explain why HyFoSy foam tends to overestimate tubal patency; the foam is compressible, so it may pass through partially obstructed tubes and give a false positive for a patent tube. The pressure used to inject the foam exacerbates this; it may increase its passage through anatomically patent tubes [23,24].

However, in reality, the tubes are physiologically obstructed by adhesions, so the picture obtained is not a reflection of what really happens in normal physiology, where these adhesions impede ciliary movement of sperm; i.e., HyFoSy may miss tubal impaired ciliary movement or mucosal damage [25].

Moreover, technical issues play a role, as the ultrasonography examination is operator-dependent and prone to acoustic shadowing, which may partially mask a blocked tube diagnosed by HSG during an X-ray examination [26-28].

The study showed a good overall agreement between the two tests and a strong statistical concordance. Critically, McNemar's test revealed systematic bias, which indicated that both tests have strong overall concordance, but they are not interchangeable. This implies that in high-risk groups or in circumstances where definitive tubal assessment is needed to shape a patient treatment plan, HSG may serve as a better tool due to false negative results.

HyFoSy is a useful non-invasive first-line screening tool in low-risk infertile women with AV uteri. However, in RV uteri, a confirmatory HSG remains essential. Clinicians should discuss HyFoSy limitations, and a comprehensive, integrated anatomical-functional evaluation is advised to reduce the odds of false reassurance, and delayed appropriate management, thereby aiming to optimize patient-centered care.

Limitations

We acknowledge the study's limitations, including its small sample size, which limits the generalizability of its

results, and the absence of cases with bilateral tubal blockage, which restricted the evaluation of negative agreement. Finally, the potential technical challenges with RV uteri may have affected the diagnostic accuracy.

Our inclusion criterion requiring normal ovulation may limit generalizability, as tubal patency assessment is often performed in women with concurrent ovulatory disorders in clinical practice.

Strengths

The prospective study design and well-defined inclusion criteria strengthen the study's internal validity. The prevalence bias was addressed by multiple statistical agreement tests (κ , Gwet's AC1). Being conducted in a real-world clinical setting enhances the study's external validity.

Suggested future works

Larger multicenter studies with a larger sample size are needed to confirm these findings and to refine imaging techniques for RV uteri. HyFoSy may ultimately be integrated with other diagnostic fertility tests as part of a comprehensive infertility workup.

Conclusions

The substantial diagnostic discrepancies between HyFoSy and HSG make HyFoSy a valuable complementary tool for infertility workup, owing to its ease of administration and non-invasive nature. However, the systematic tendency of HyFoSy to overestimate tubal patency, especially among women with RV uterus, highlights the need for careful patient stratification according to the uterus anatomy. A tailored diagnostic approach, using HyFoSy as the first-line screening in women with AV uteri, is recommended, whereas direct referral to HSG is advised for RV uteri or when a definitive assessment is crucial for guiding treatment strategy. These findings should be interpreted with caution, given the small sample size and the lack of bilateral tubal blockage cases in our cohort, which warrants larger studies with a more balanced case distribution to validate the current results.

Disclosures

1. Institutional review board statement: This study was approved by the Ethical Committee of Al-Kindy College of Medicine (approval number 217, dated 30/04/2025).
2. Assistance with the article: None.
3. Financial support and sponsorship: None.
4. Conflicts of interest: None.

References

- Cassiman EG, Harter S, Mougel R, Mezan De Malartic C, Bertholdt C, Morel O, Agopianz M. Is hysterosalpingo-foam sonography the new gold standard for assessing tubal patency? A systematic review and meta-analysis. *Reprod Biomed Online* 2025; 50: 104380. DOI: 10.1016/j.rbmo.2024.104380.
- Tanaka K, Chua J, Cincotta R, Ballard EL, Duncombe G. Hysterosalpingo-foam sonography (HyFoSy): tolerability, safety and the occurrence of pregnancy post-procedure. *Aust N Z J Obstet Gynaecol* 2018; 58: 114-118.
- Engels V, Medina M, Antolín E, Ros C, Amaro A, De-Guirior C, et al. Feasibility, tolerability, and safety of hysterosalpingo-foam sonography (hyfosy). Multicenter, prospective Spanish study. *J Gynecol Obstet Hum Reprod* 2021; 50: 102004. DOI: 10.1016/j.jogoh.2020.102004.
- Serrano González L, Pérez-Medina T, Bueno Olalla B, Royuela A, de Los Reyes De La Cuesta M, Saéz de la Mata D, et al. Is hysterosalpingo-foam sonography (HyFoSy) more tolerable in terms of pain and anxiety than hysterosalpingography (HSG)? A prospective real-world setting multicentre study. *BMC Womens Health* 2022; 22: 41. DOI: 10.1186/s12905-022-01606-3.
- Lo Monte G, Capobianco G, Piva I, Caserta D, Dessole S, Marci R. Hysterosalpingo contrast sonography (HyCoSy): let's make the point! *Arch Gynecol Obstet* 2015; 291: 19-30.
- Boned-López J, Alcázar JL, Errasti T, Ruiz-Zambrana A, Rodriguez I, Pascual MA, Guerriero S. Severe pain during hysterosalpingo-contrast sonography (HyCoSy): a systematic review and meta-analysis. *Arch Gynecol Obstet* 2021; 304: 1389-1398.
- Frinking P, Segers T, Luan Y, Tranquart F. Three decades of ultrasound contrast agents: a review of the past, present and future improvements. *Ultrasound Med Biol* 2020; 46: 892-908.
- Lim SL, Jung JJ, Yu SL, Rajesh H. A comparison of hysterosalpingo-foam sonography (HyFoSy) and hysterosalpingo-contrast sonography with saline medium (HyCoSy) in the assessment of tubal patency. *Eur J Obstet Gynecol Reprod Biol* 2015; 195: 168-172.
- Rajesh H, Lim SL, Yu SL. Hysterosalpingo-foam sonography: patient selection and perspectives. *Int J Womens Health* 2017; 9: 23-32.
- Tsakos E, Xydias EM, Emmanouil V, Koutini M, Ntanika A, Prior M, et al. O-271 Application of HyFoSy in the assessment of fallopian tube patency compared to HyCoSy and HS; results of a systematic review and meta-analysis. *Hum Reprod* 2023; 38 (Suppl 1): dead093.325. DOI: 10.1093/humrep/dead093.325.
- Kamphuis D, van Eekelen R, van Welie N, Dreyer K, van Rijswijk J, van Hooff MHA, et al. Hysterosalpingo-foam sonography versus hysterosalpingography during fertility workup: an economic evaluation alongside a randomized controlled trial. *Hum Reprod* 2024; 39: 1222-1230.
- Bohilțea RE, Mihai BM, Stănică CD, Gheorghe CM, Berceanu C, Dima V, et al. Technical tips and tricks after 10 years of HyFoSy for tubal patency testing. *J Clin Med* 2022; 11: 5946. DOI: 10.3390/jcm11195946.
- Nori W, Helmi ZR. Can follicular fluid 8-oxo-2'-deoxyguanosine predict the clinical outcomes in ICSI cycle among couples with normospermia male? *Obstet Gynecol Sci* 2023; 66: 430-440.
- Van Welie N, van Rijswijk J, Dreyer K, van Hooff MH, Peter de Bruin J, Verhoeve HR, et al. Can hysterosalpingo-foam sonography replace hysterosalpingography as first-choice tubal patency test? A randomized non-inferiority trial. *Hum Reprod* 2022; 37: 969-979.
- Ramos J, Caligara C, Santamaría-López E, González-Ravina C, Prados N, Carranza F, et al. Diagnostic accuracy study comparing hysterosalpingo-foam sonography and hysterosalpingography for fallopian tube patency assessment. *J Clin Med* 2021; 10: 4169. DOI: 10.3390/jcm10184169.
- McHugh ML. Interrater reliability: the kappa statistic. *Biochem Med (Zagreb)* 2012; 22: 276-282.
- Emanuel MH, van Vliet M, Weber M, Exalto N. First experiences with hysterosalpingo-foam sonography (HyFoSy) for office tubal patency testing. *Hum Reprod* 2011; 27: 114-117.
- Li Y, Chen X, Wang Q, Wang J. Factors influencing the visualization of fallopian tubes in hysterosalpingo-contrast sonography (HyCoSy) – the value of multimodal HyCoSy in visualizing the fallopian tubes. *J Ultrasound Med* 2024; 43: 1957-1967.
- Fu F, Zhu YF, Chen YF, Zhuang JJ, Zheng WT, Liang RX, Ye Q. Diagnostic value of multimodal hysterosalpingo-contrast sonography combined with negative intrauterine contrast-enhanced ultrasound in female infertility. *BMC Womens Health* 2025; 25: 62. DOI: 10.1186/s12905-025-03598-2.
- Revzin MV, Moshiri M, Katz DS, Pellerito JS, Gettle LM, Menias CO. Imaging evaluation of fallopian tubes and related disease: a primer for radiologists. *Radiographics* 2020; 40: 1473-1501.
- Exacoustos C, Pizzo A, Lazzeri L, Pietropolli A, Piccione E, Zupi E. Three-dimensional hysterosalpingo contrast sonography with gel foam: methodology and feasibility to obtain 3-dimensional volumes of tubal shape. *J Minim Invasive Gynecol* 2017; 24: 827-832.
- Grigovich M, Kacharia VS, Bharwani N, Hemingway A, Mijatovic V, Rodgers SK. Evaluating fallopian tube patency: what the radiologist needs to know. *Radiographics* 2021; 41: 1876-1896.
- Rajesh H, Lim SL, Yu SL. Hysterosalpingo-foam sonography: patient selection and perspectives. *Int J Womens Health* 2016; 9: 23-32.
- Piccioni MG, Riganelli L, Filippi V, Fuggetta E, Colagiovanni V, Imperiale L, et al. Sonohysterosalpingography: comparison of foam and saline solution. *J Clin Ultrasound* 2017; 45: 67-71.
- Zafarani F, Ghaffari F, Ahmadi F, Mehranjani MS, Shahrzad G. Hysterosalpingography in the assessment of proximal tubal pathology: a review of congenital and acquired abnormalities. *Br J Radiol* 2021; 94: 20201386. DOI: 10.1259/bjr.20201386.
- Le Lous M, Klein M, Tesson C, Berthelemy J, Lavoue V, Jannin P. Metrics used to evaluate obstetric ultrasound skills on simulators: a systematic review. *Eur J Obstet Gynecol Reprod Biol* 2021; 258: 16-22.
- Abdulqader SK, Nori W, Akram NN, Al-Kinani M. Radiological modalities for the assessment of fetal growth restriction: a comprehensive review. *Al-Kindy Col Med J* 2024; 20: 4-13. DOI: 10.47723/nz221421.
- Wong SC, Yung KS, Chan RL, Luk WH. Hysterosalpingographic findings from uterus to peritoneal cavity: a pictorial essay. *Hong Kong J Radiol* 2023; 26: 153-160.